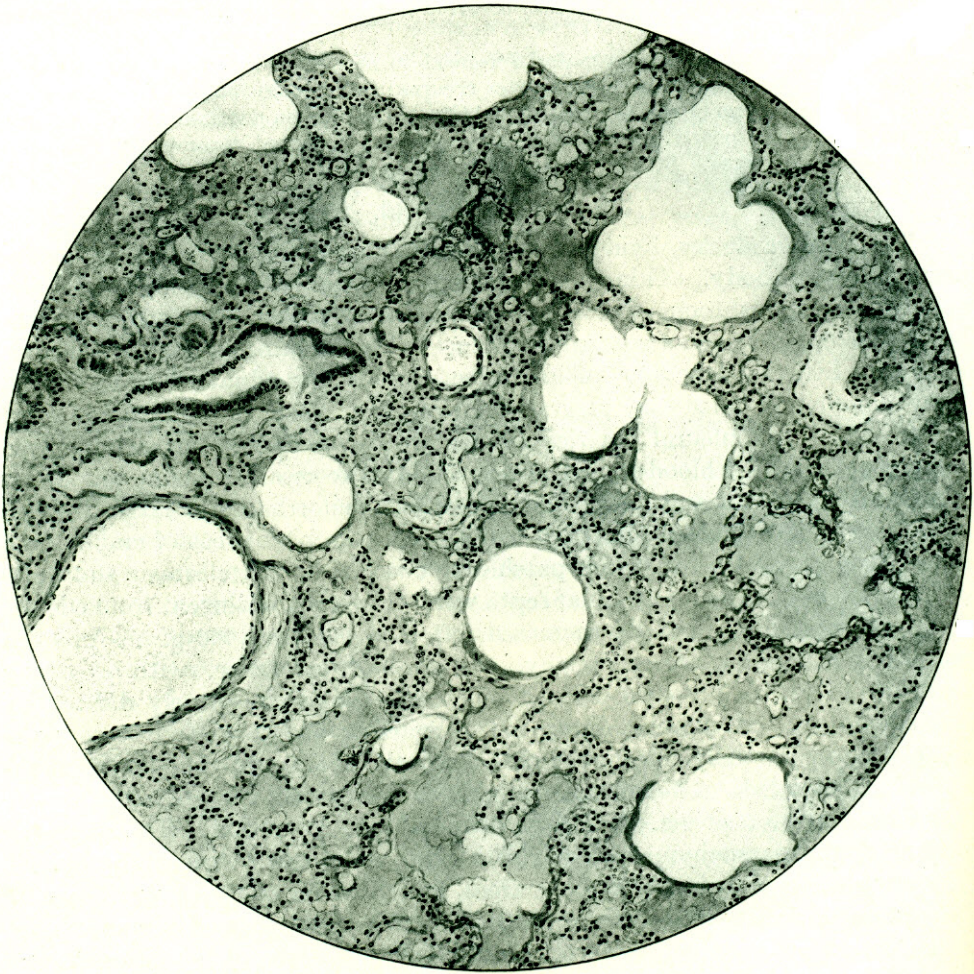

FIG. 2.—Case 2. Lung. Poisoning with phosgene and blue cross gas. Intense alveolar edema, dilatation of atria, stasis of leucocytes in capillaries. Epithelium of small bronchi is intact