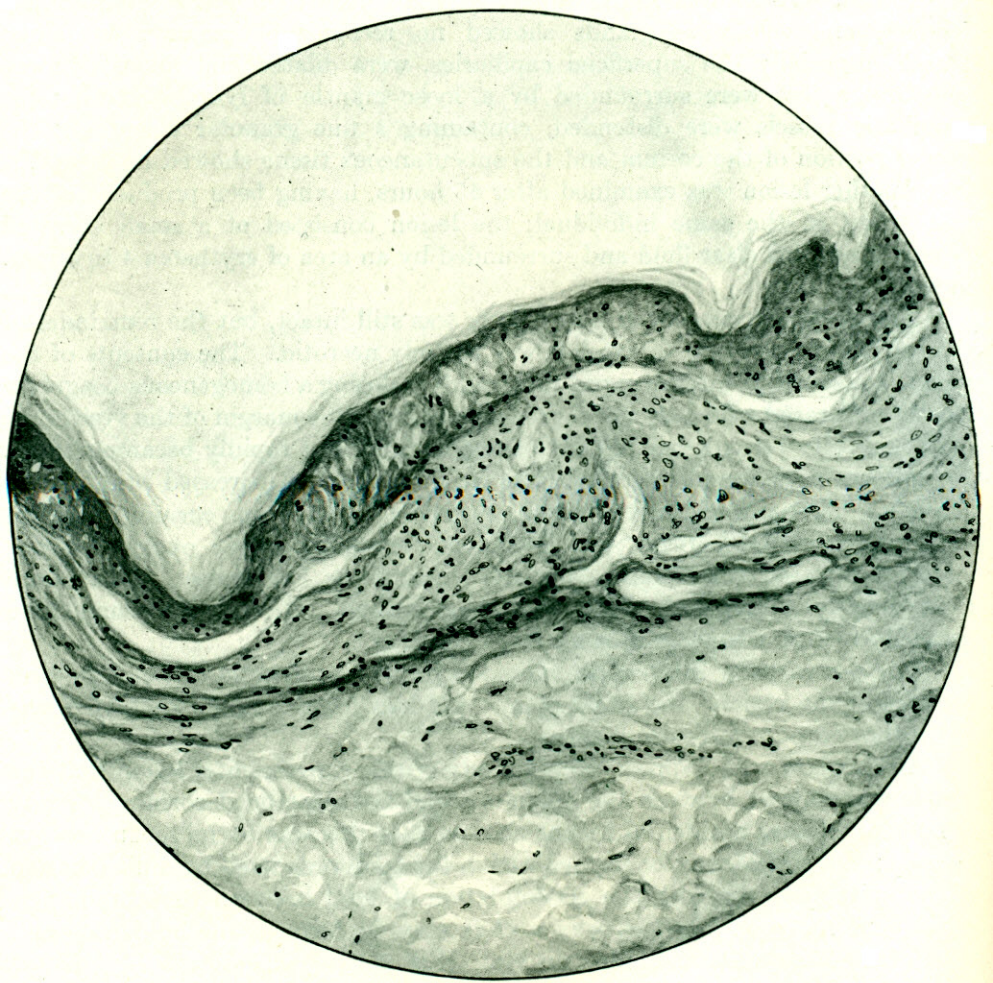

FIG. 4.—Case 8. Mustard-gas burn of skin of 2 days' duration. Necrosis of epidermis, with beginning of intra-epidermal vesicle formation