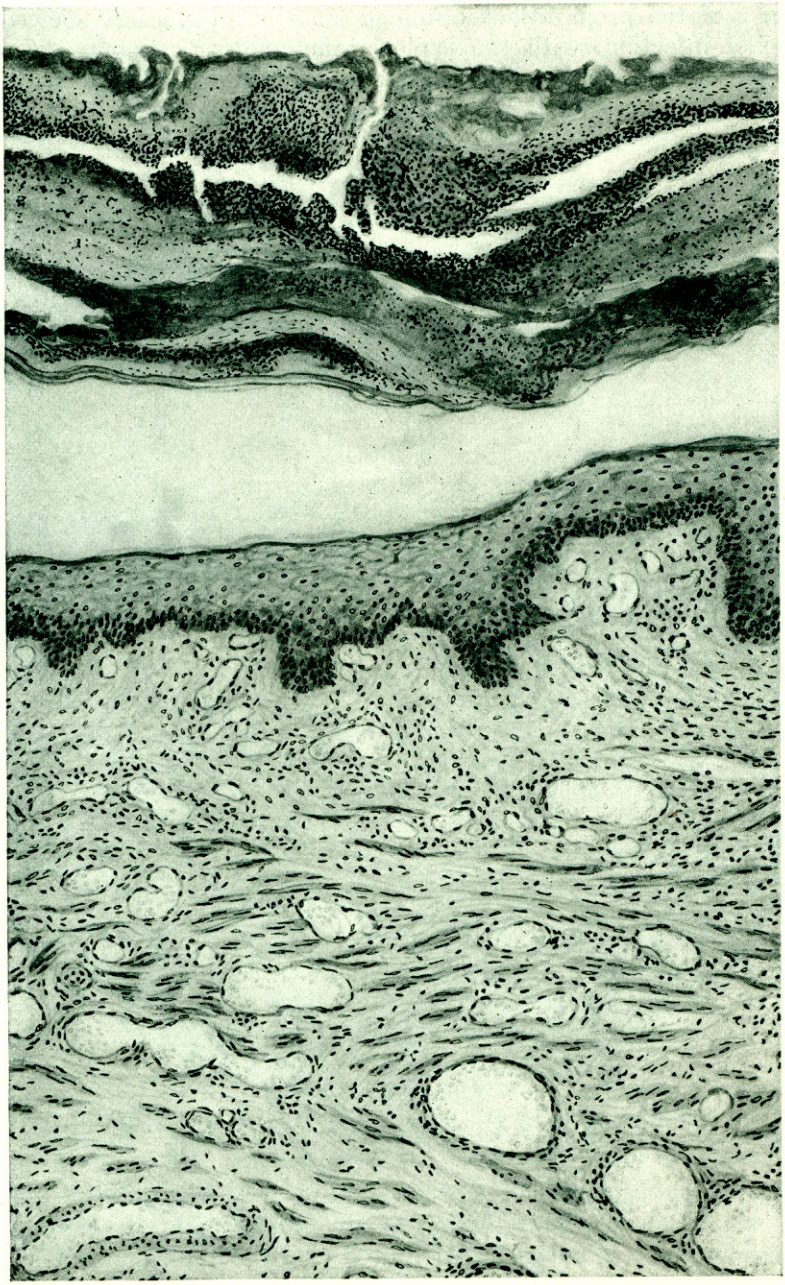

FIG. 5.—Case 89. Mustard-gas burn of 20 days' duration. Regeneration of new epithelium beneath crust of necrotic original epithelium. Hyperemia. Absence of inflammatory reaction