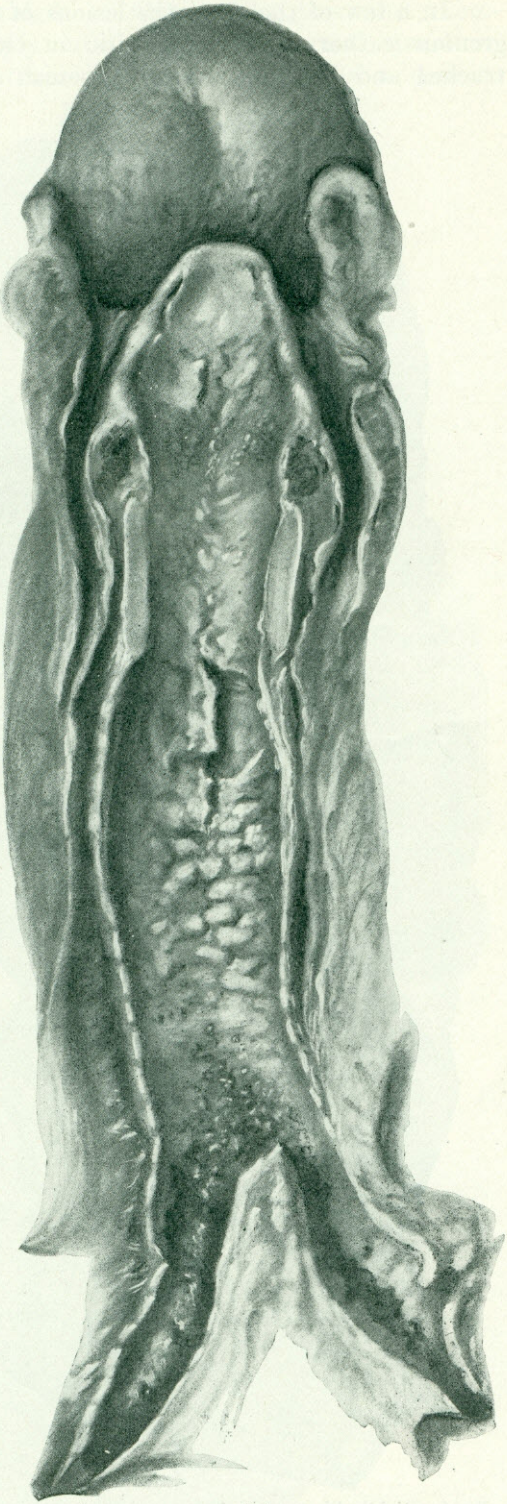

FIG. 8.—Mustard-gas poisoning. False membrane extending from epiglottis through entire trachea into bronchi