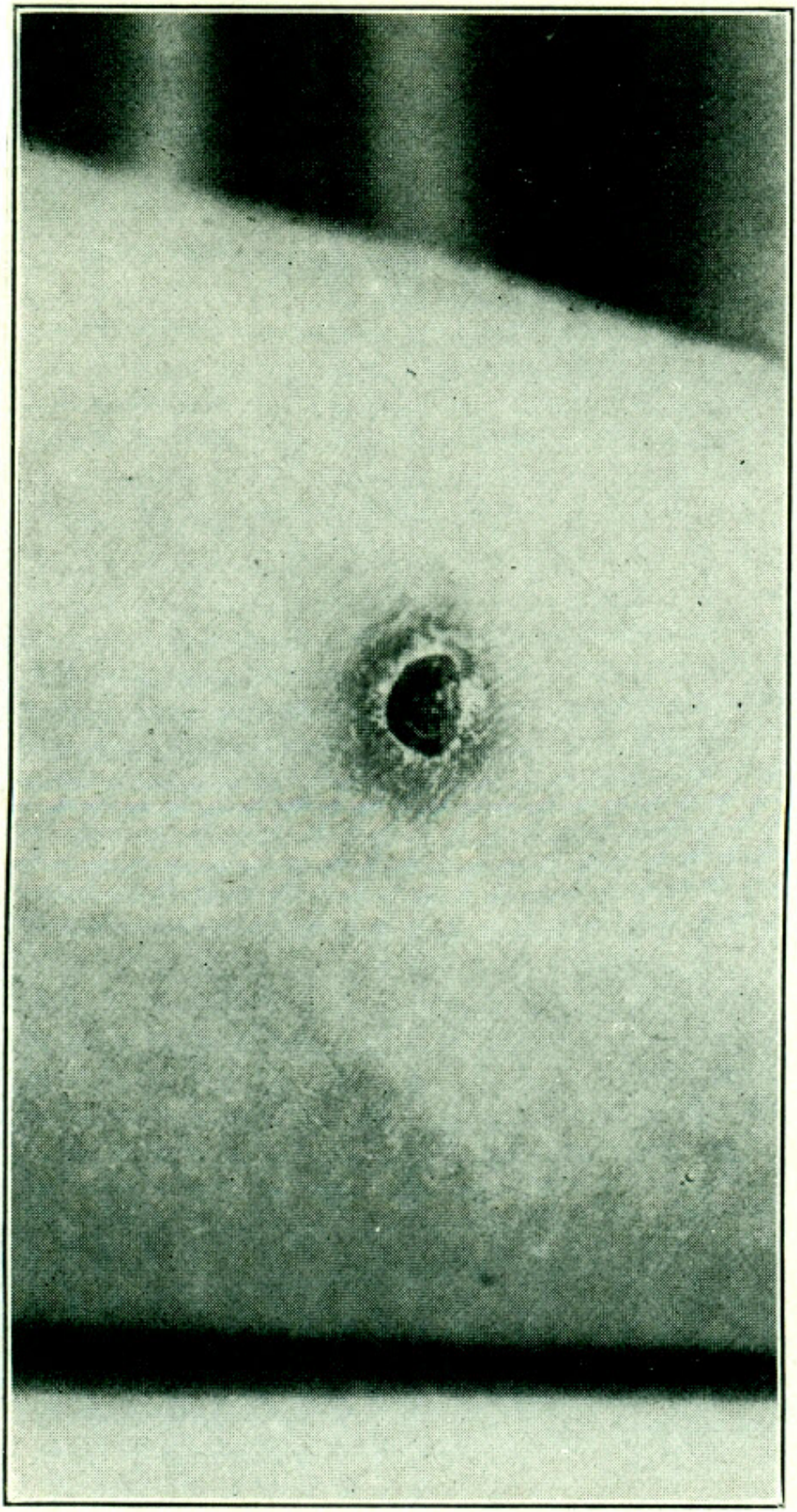

FIG. 100.—Mustard-gas lesion at 18 days