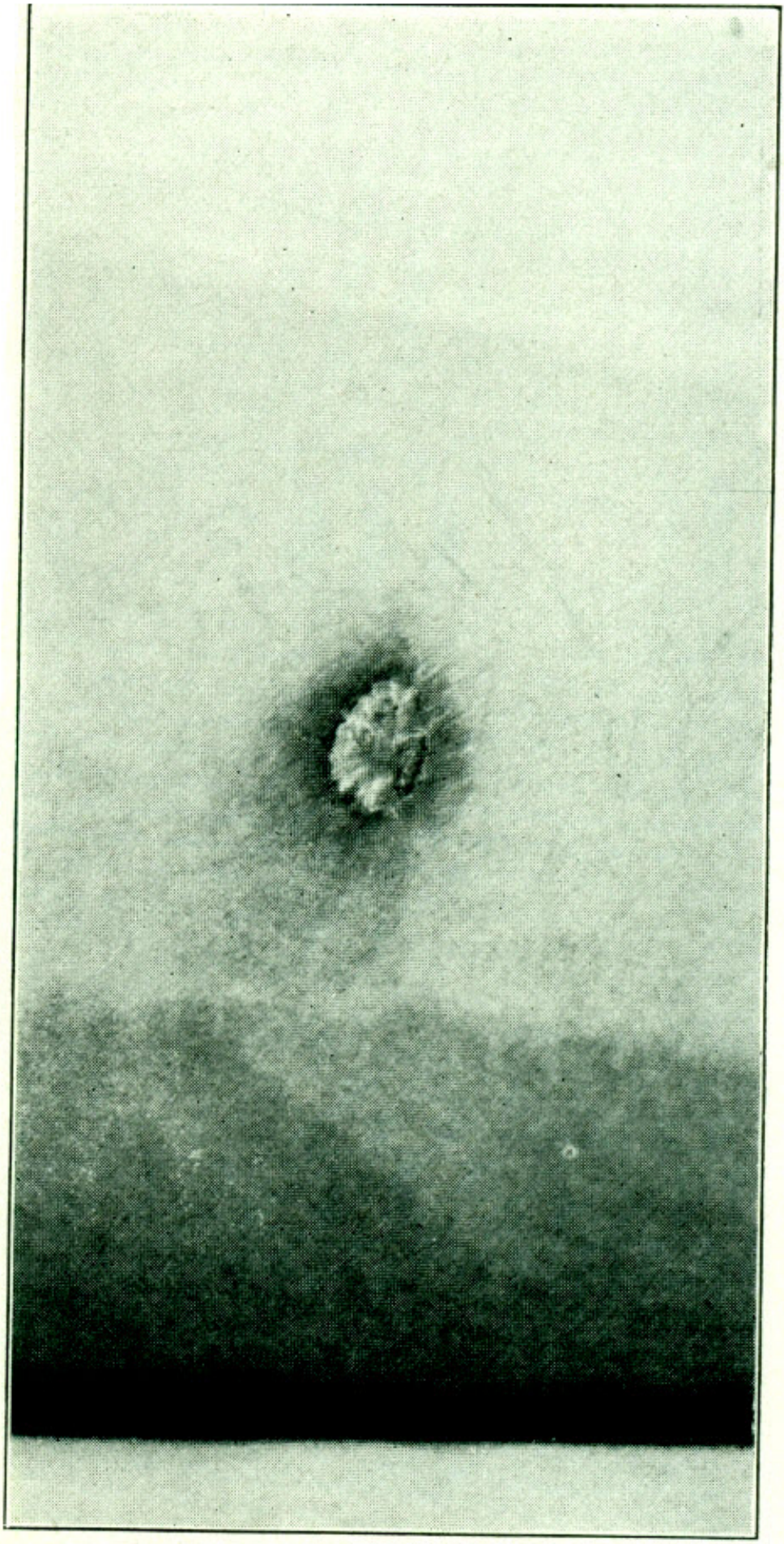

FIG. 101.—Mustard-gas lesion at 20 days