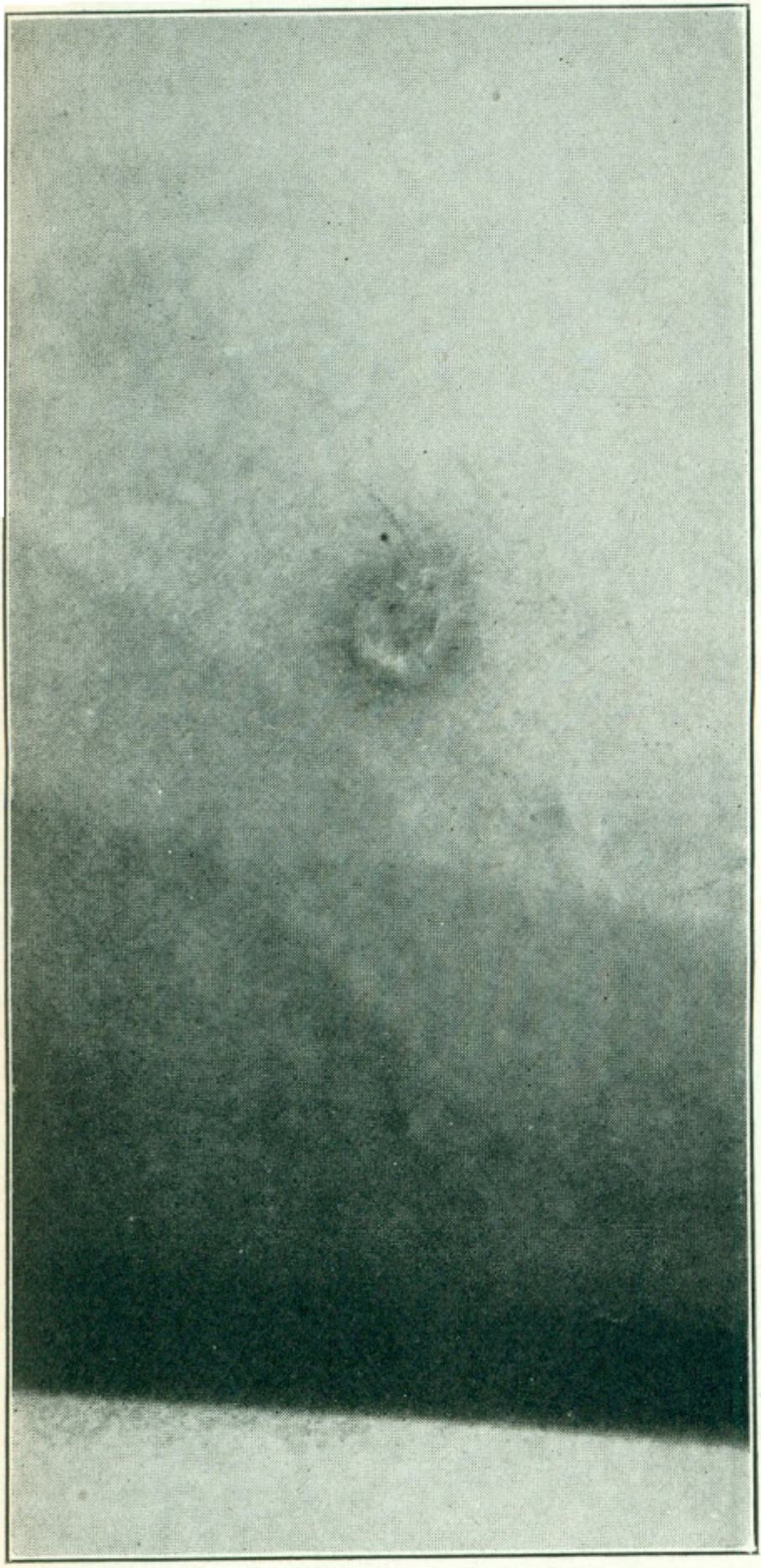

FIG. 102.—Mustard-gas lesion at 49 days