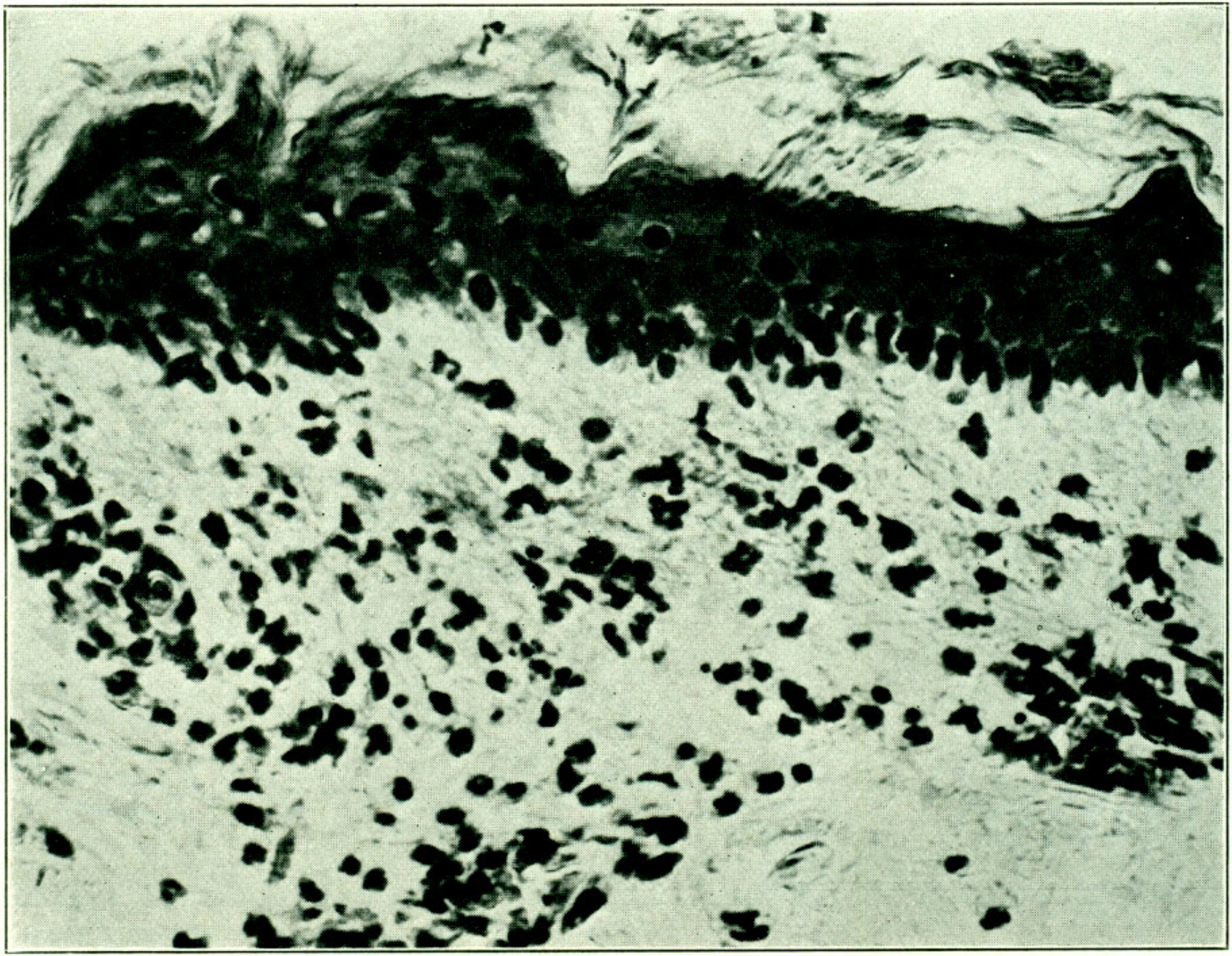

FIG. 110.—Human skin 36 hours after application of mustard gas. High-power view at border of lesion, showing changes in epidermis and leucocyte infiltration and edema of papillary layer