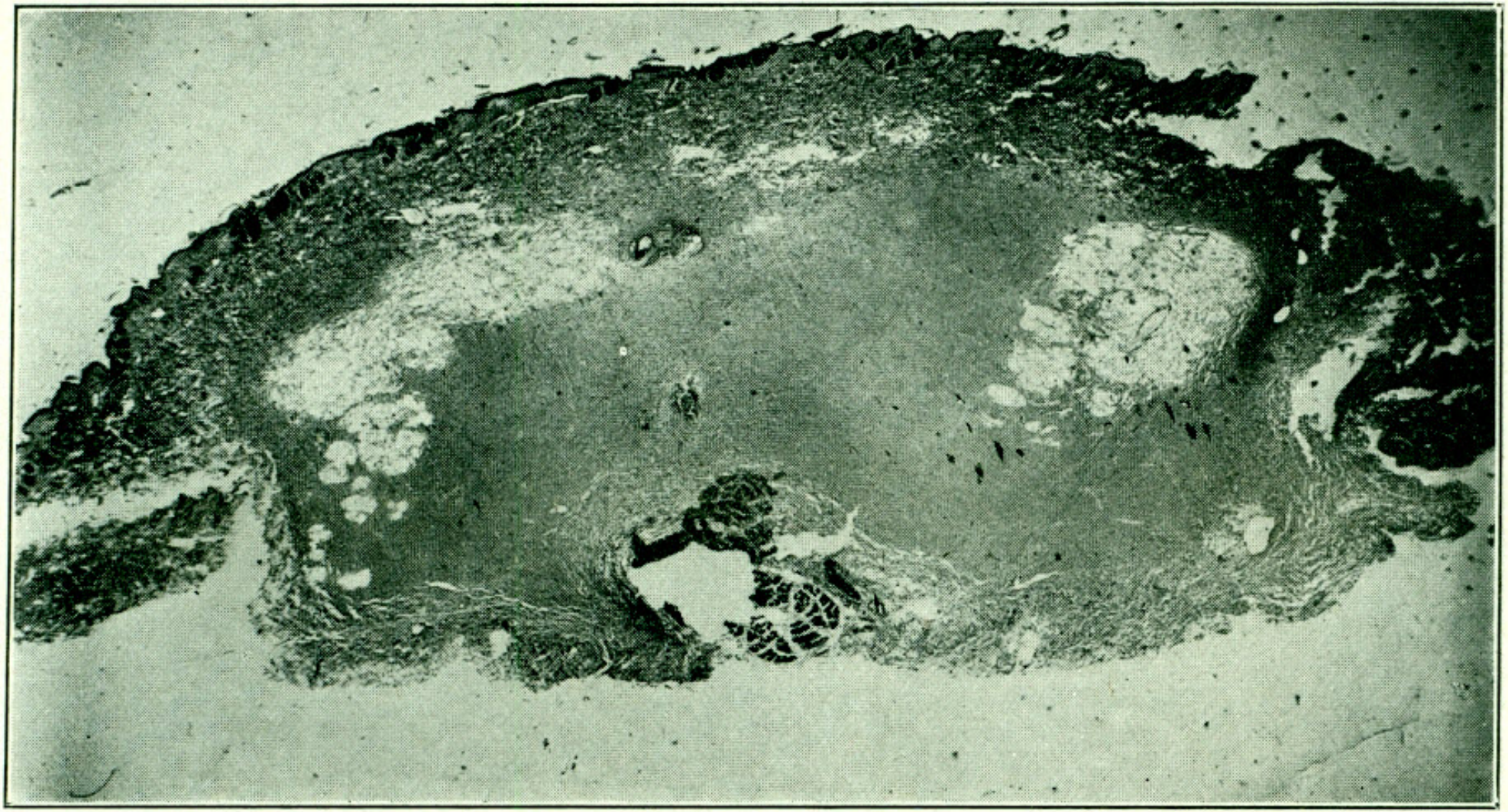

FIG. 115.—Rabbit. Low-power view of mustard-gas lesion in rabbit two hours after application. Extreme subcutaneous edema. Epidermis but slightly changed