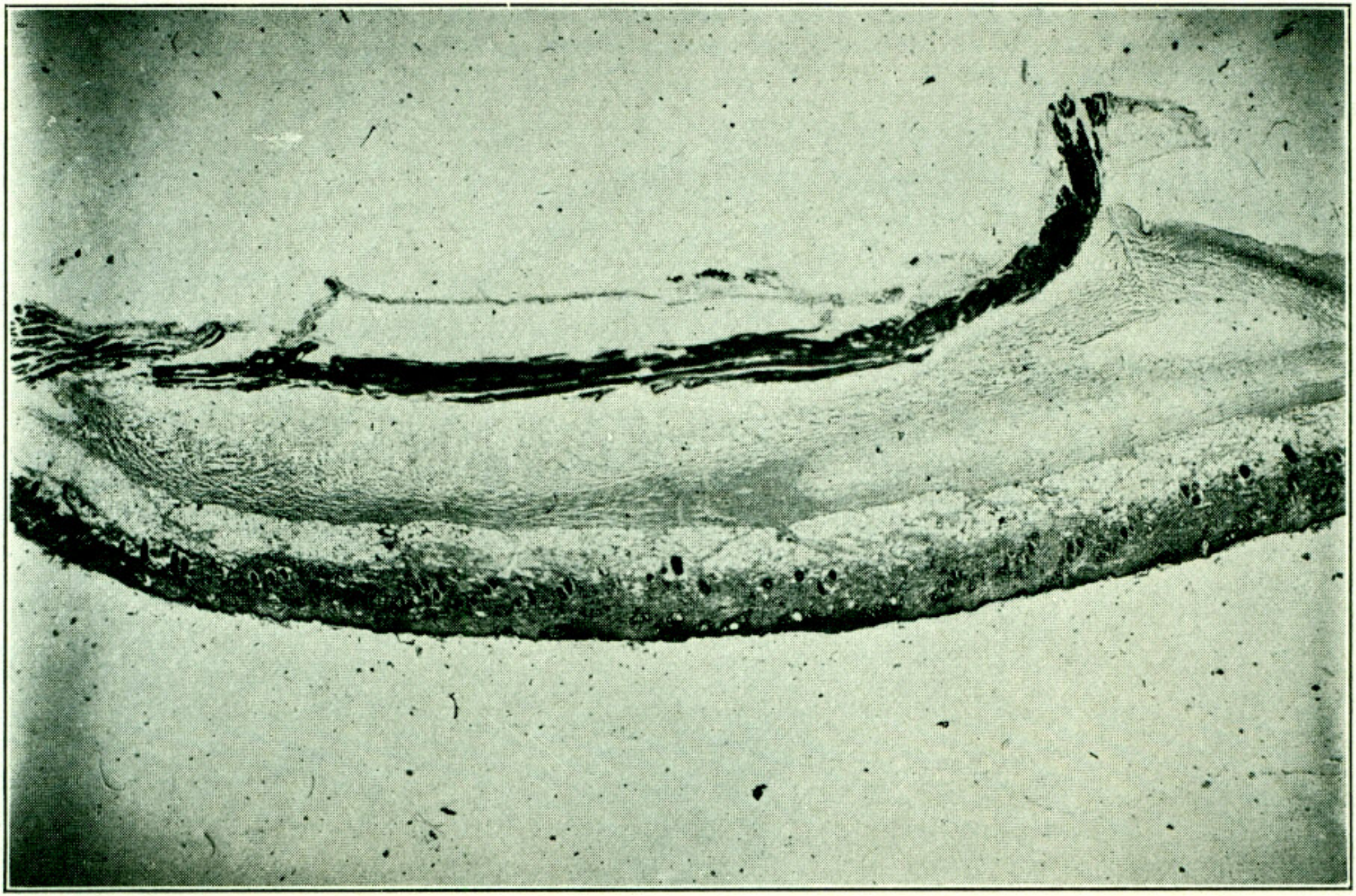

FIG. 116.—Guinea pig. Low-power view of mustard-gas lesion five and one-half hours after application. Extreme subcutaneous edema. Epidermis necrosed in center of lesion