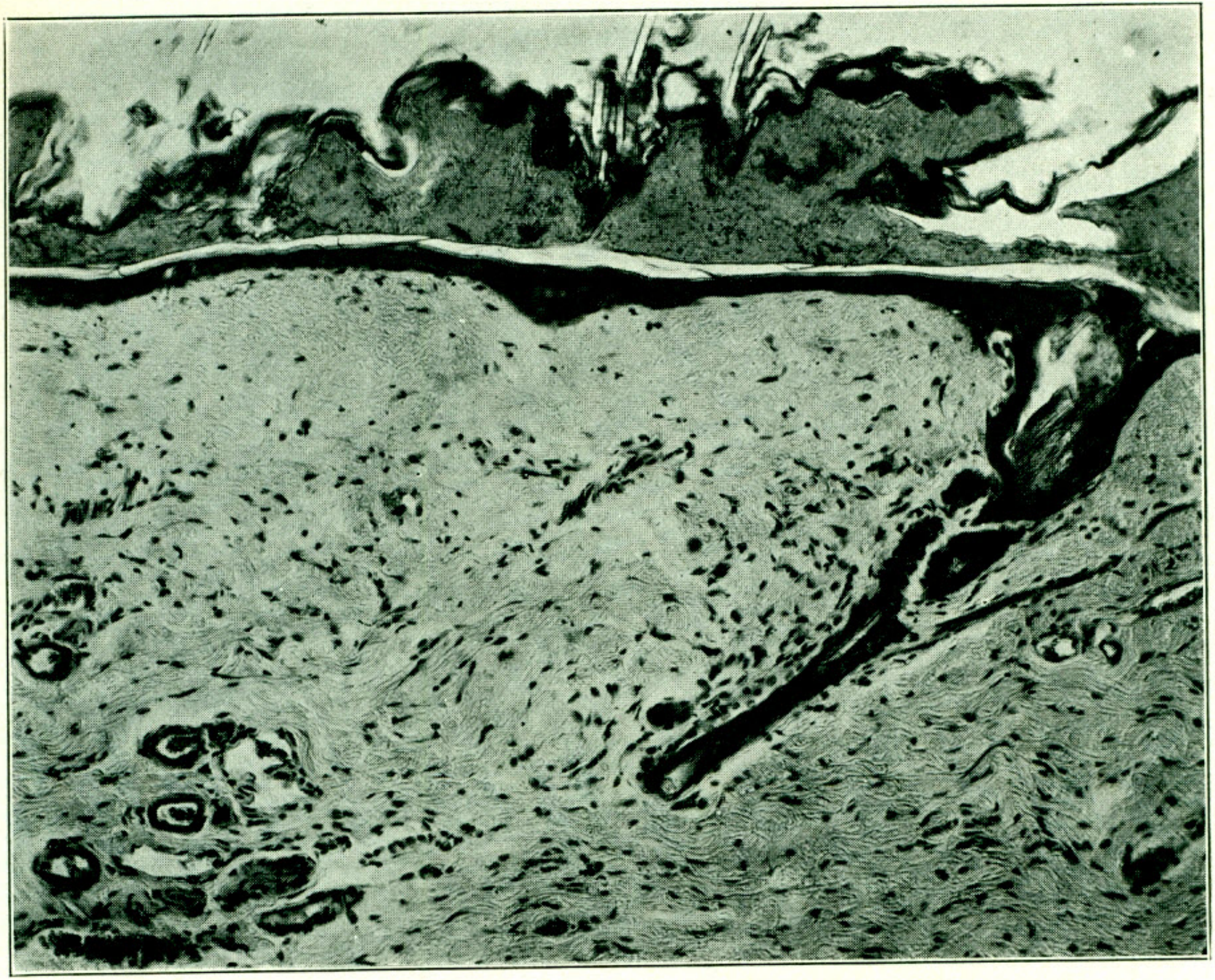

FIG. 123.—Rabbit. Periphery of same lesion as Figure 122. Area of less damage