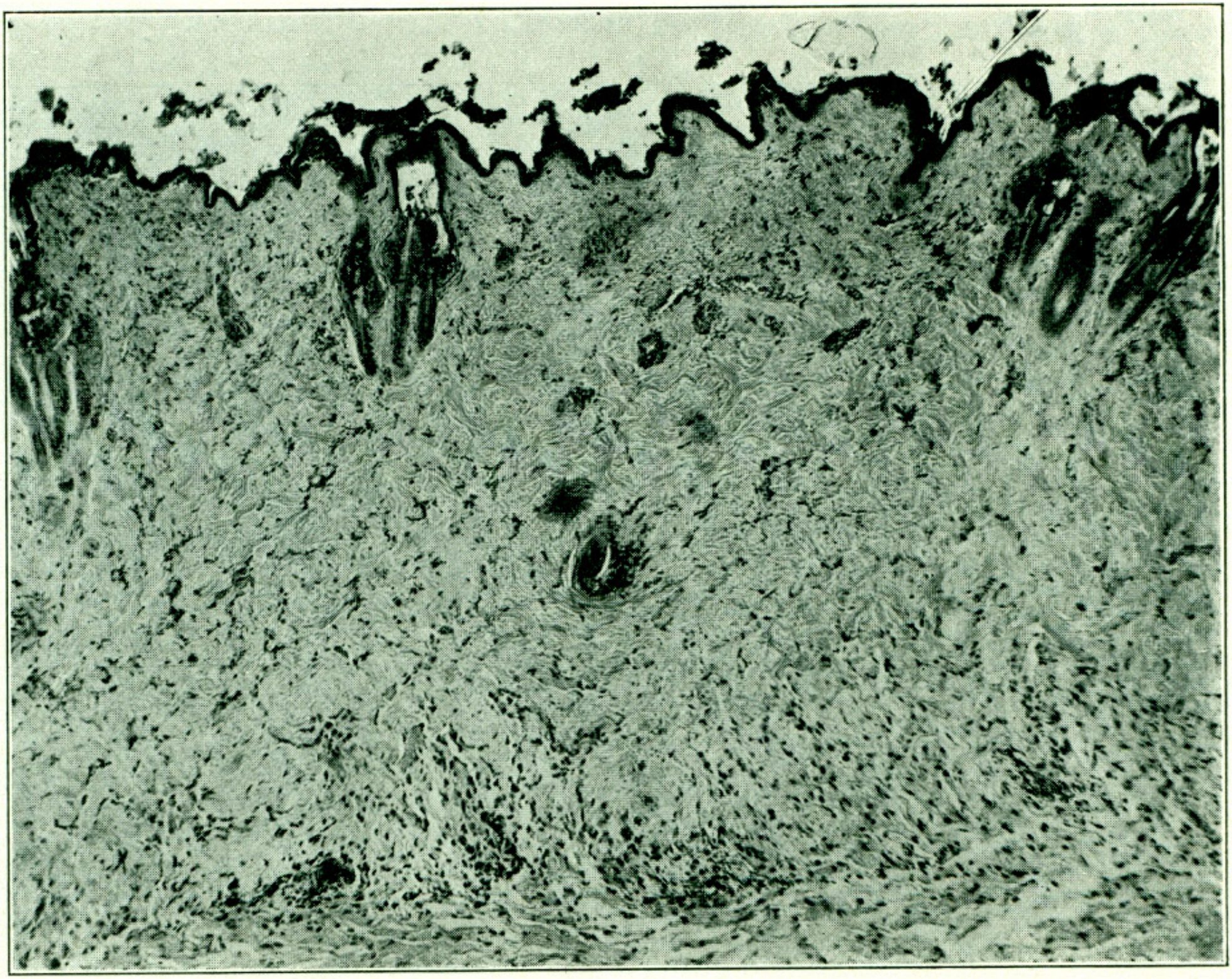

FIG. 124.—Rabbit. Six days after application of mustard gas, untreated. Border of lesion. Necrosis less marked. Beginning repair