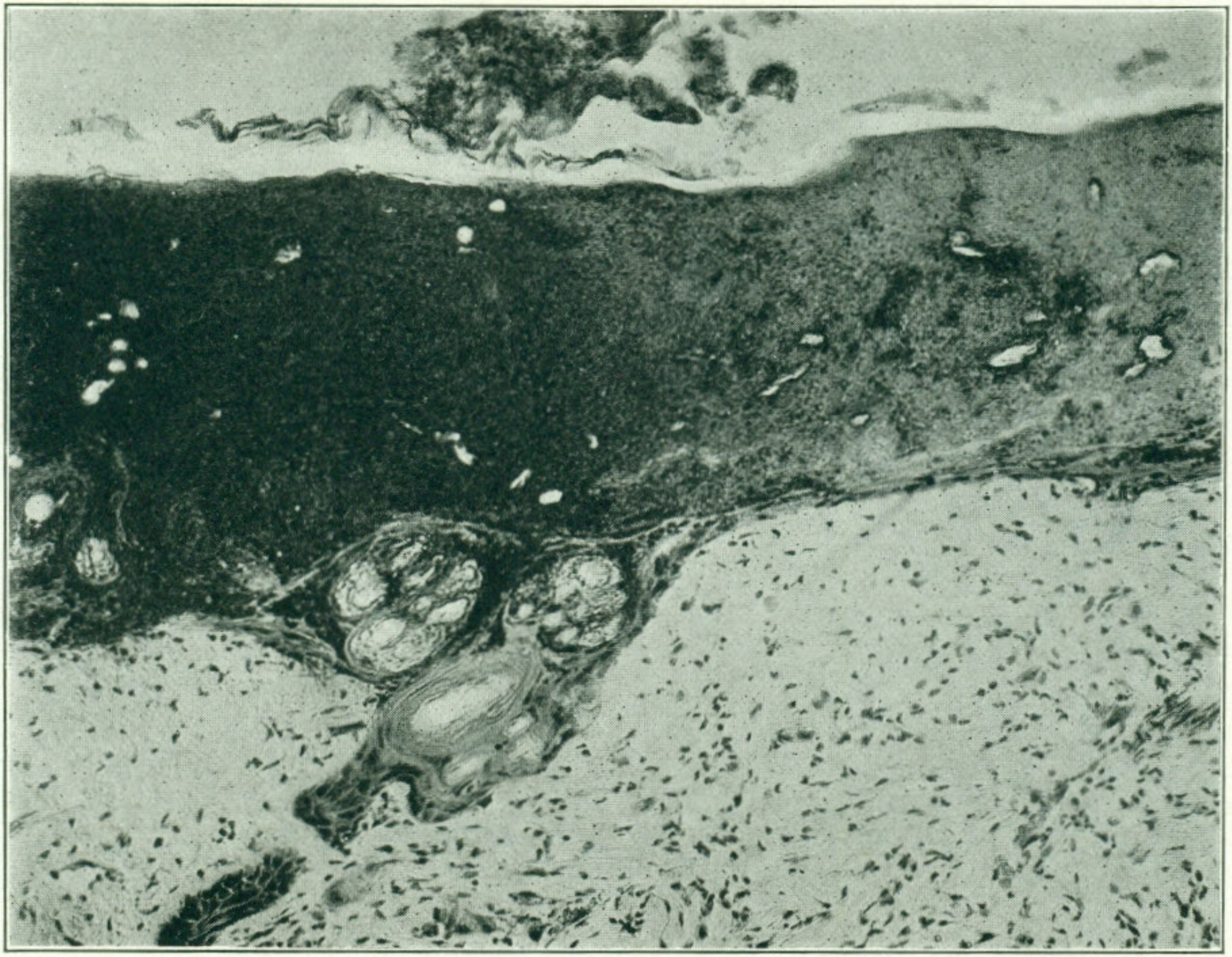

FIG. 126.—Rabbit. Six days after application, untreated. Adherent slough, representing the necrotic epidermis and upper portion of the corium, involving the hair follicles