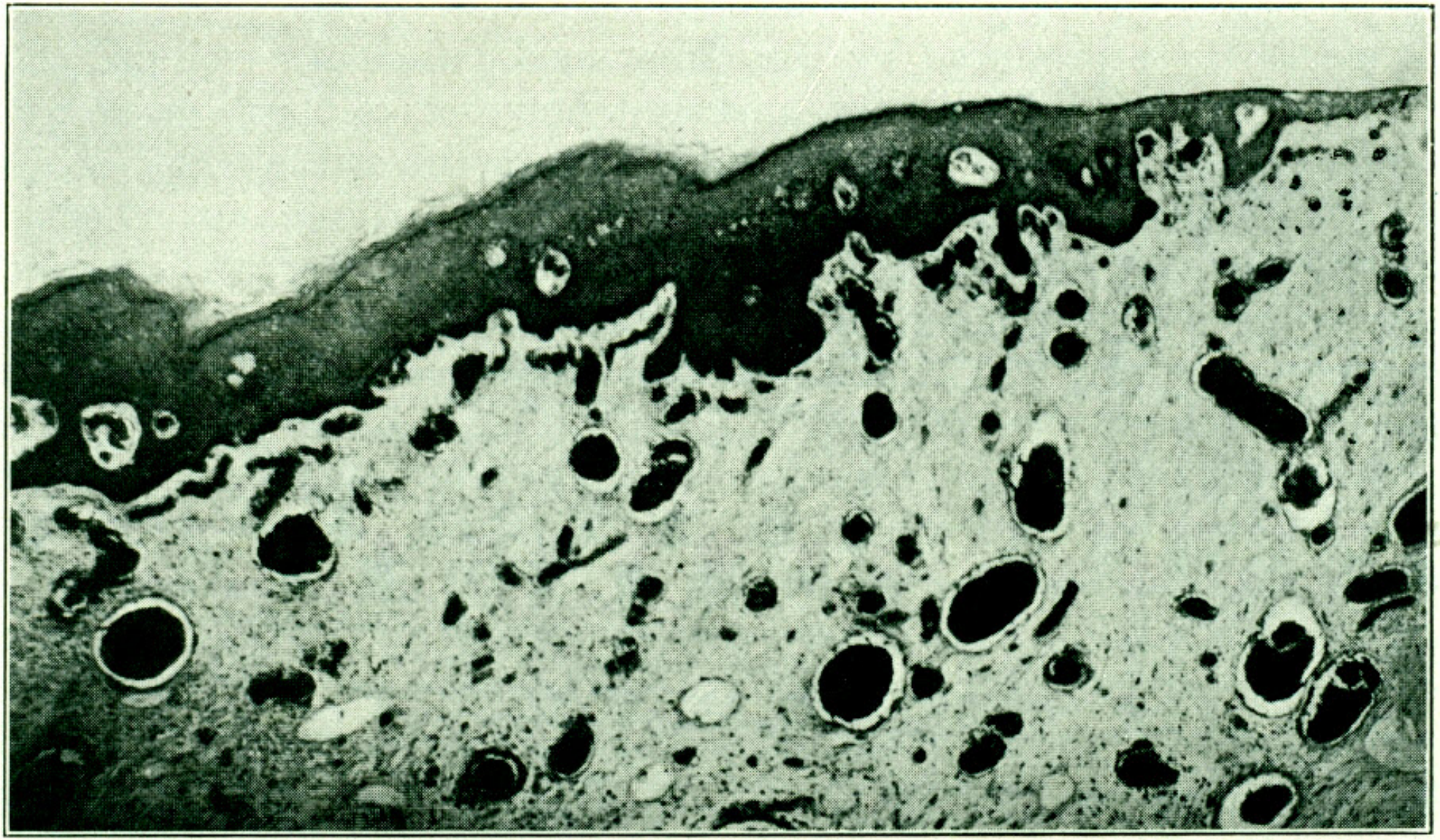

FIG. 127.—Section of skin of penis, eight days after exposure to strong concentration of mustard-gas vapor. Intense hyperemia