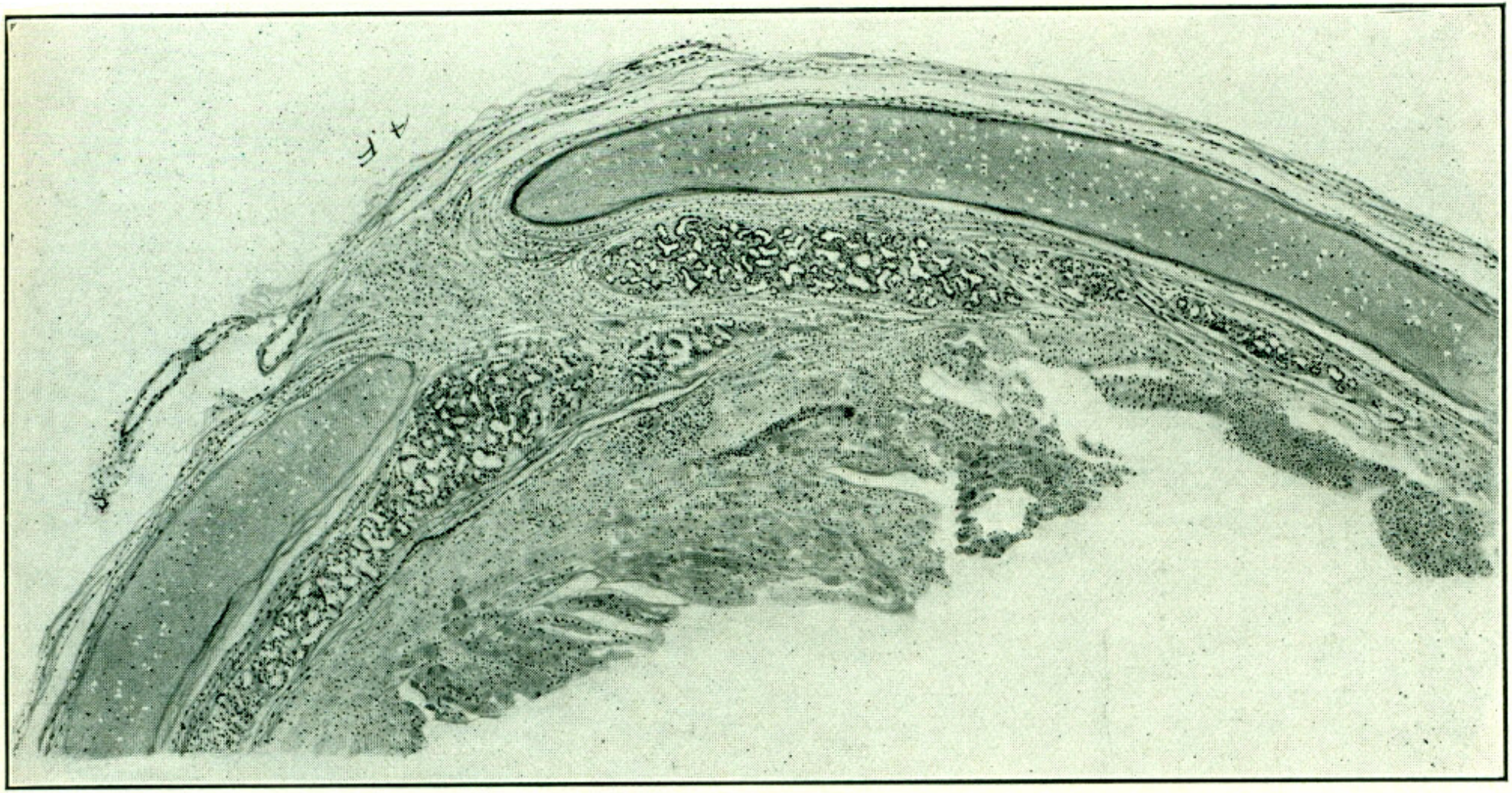

FIG. 12.—Mustard-gas burn. Deep-seated necrosis of bronchial mucosa