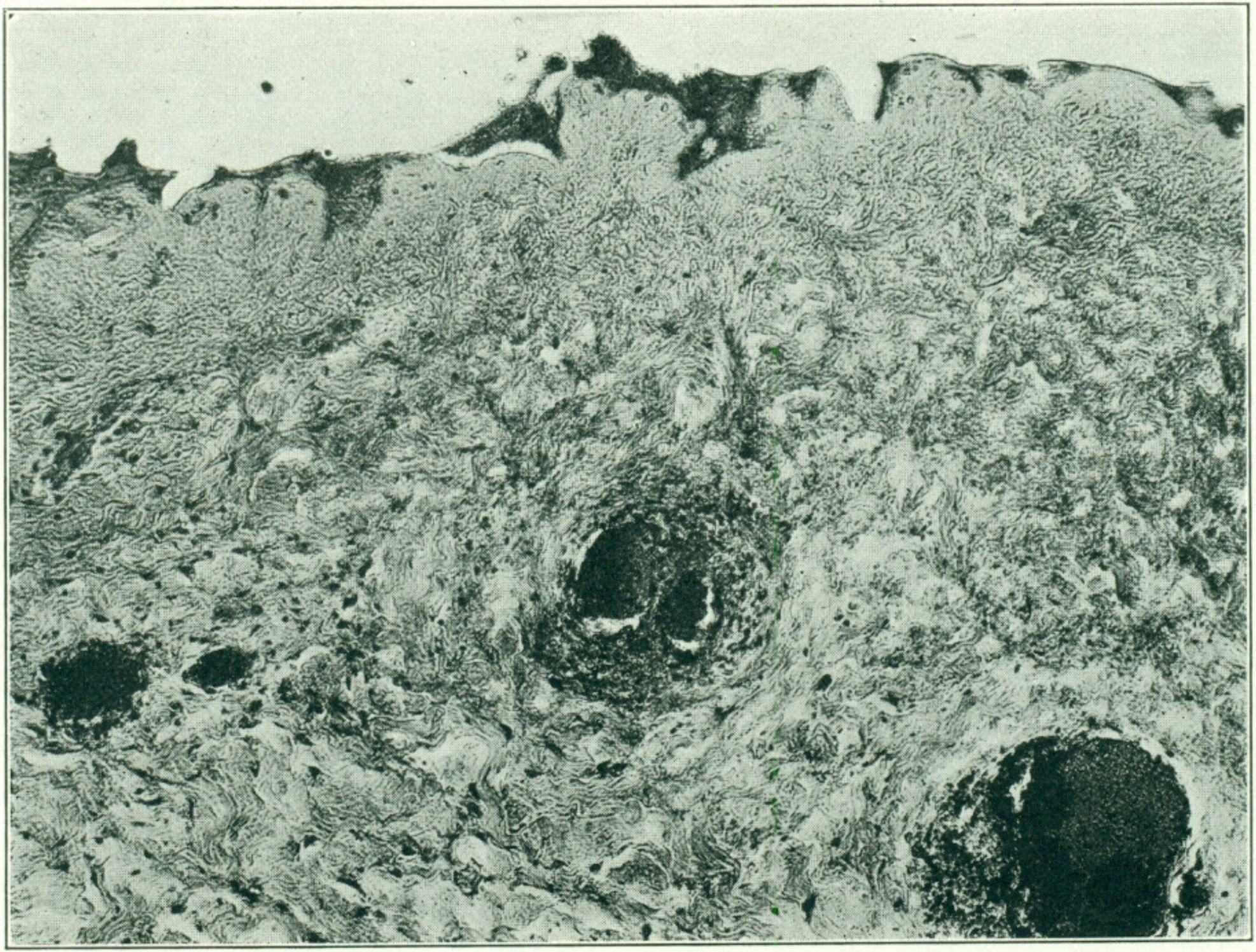

FIG. 131.—Section of skin from same case as Figure 130. Area of collapsed vesicles; necrosis of epidermis and corium; congestion of vessels