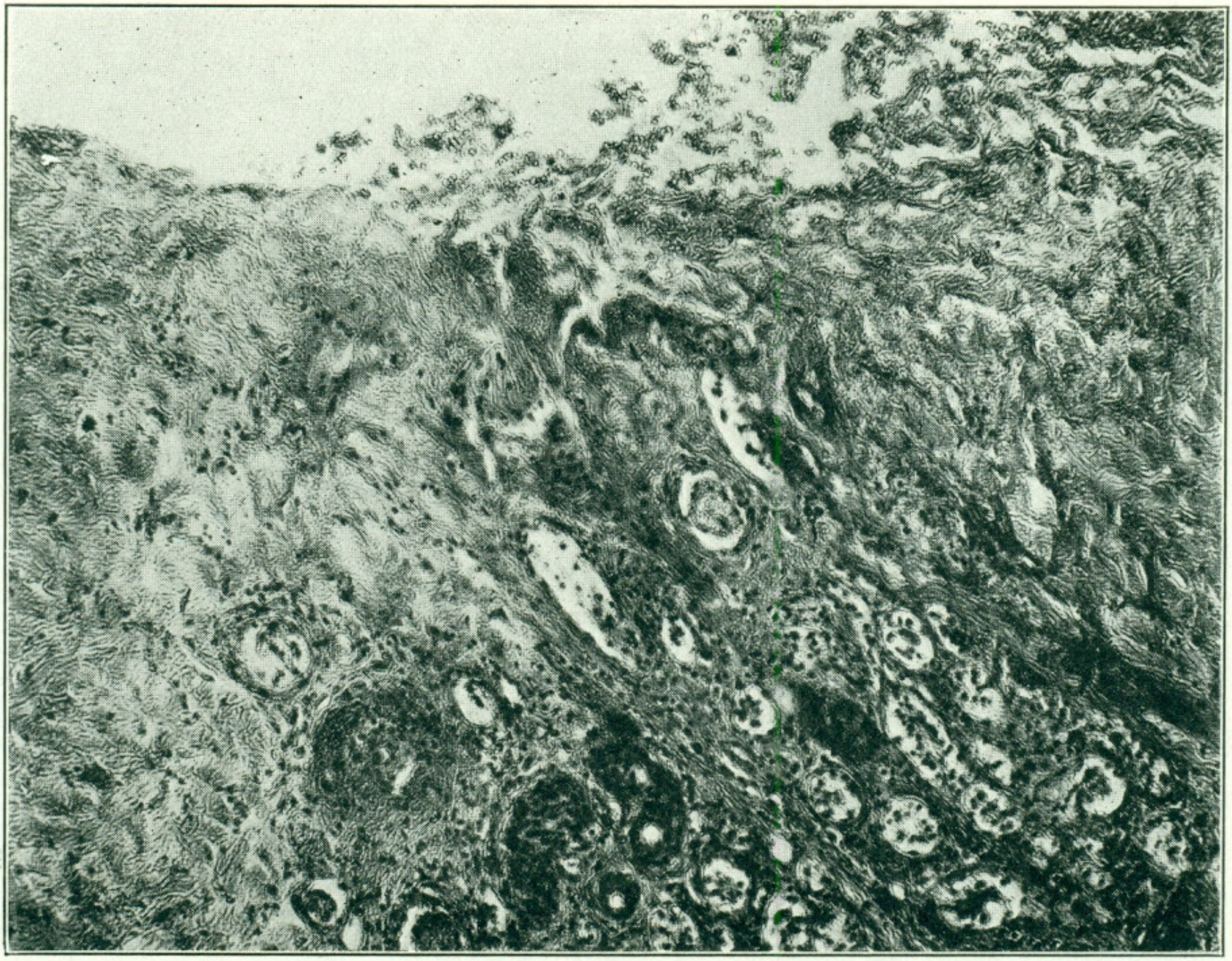

FIG. 132.—Skin from axilla of same patient as Figure 130. Necrosis of skin to the depth of the large sweat glands. These show also partial necrosis with some early regeneration