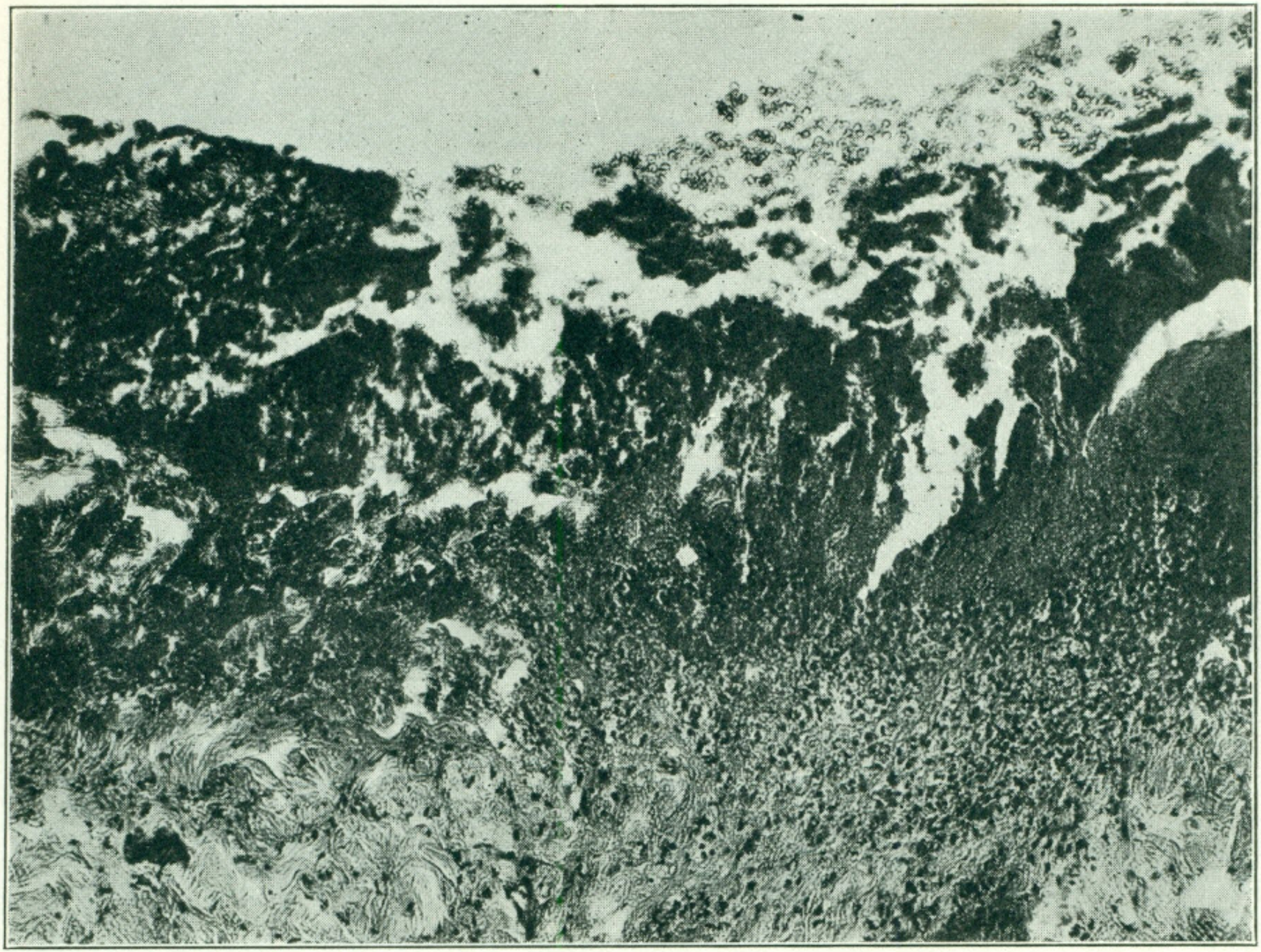

FIG. 133.—Infected gangrenous area from skin of back