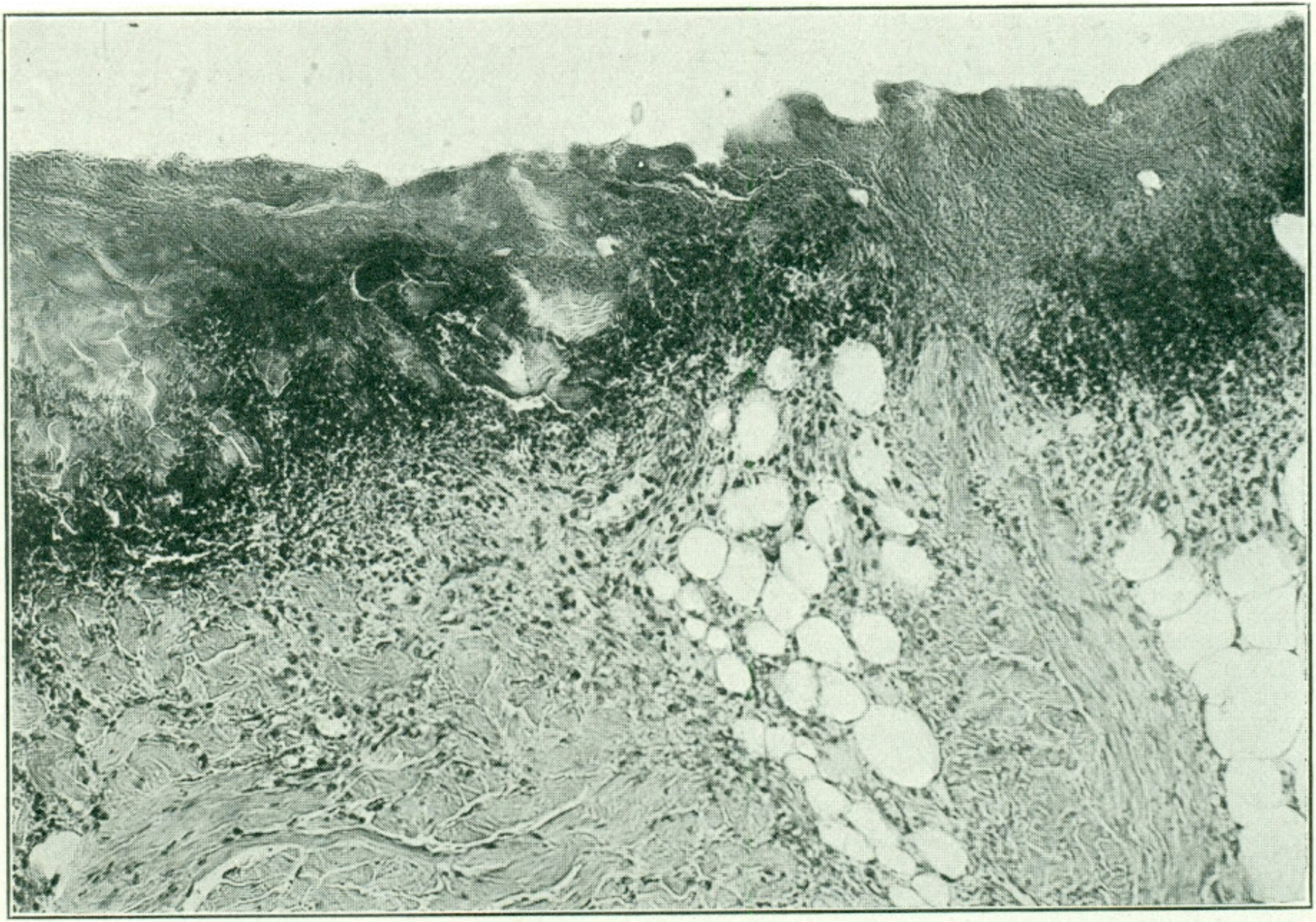

FIG. 136.—Microscopic appearance of mustard-gas decubitus four weeks after exposure. Destruction of tissue too great for regeneration. Necrosis extends below the level of the sweat glands