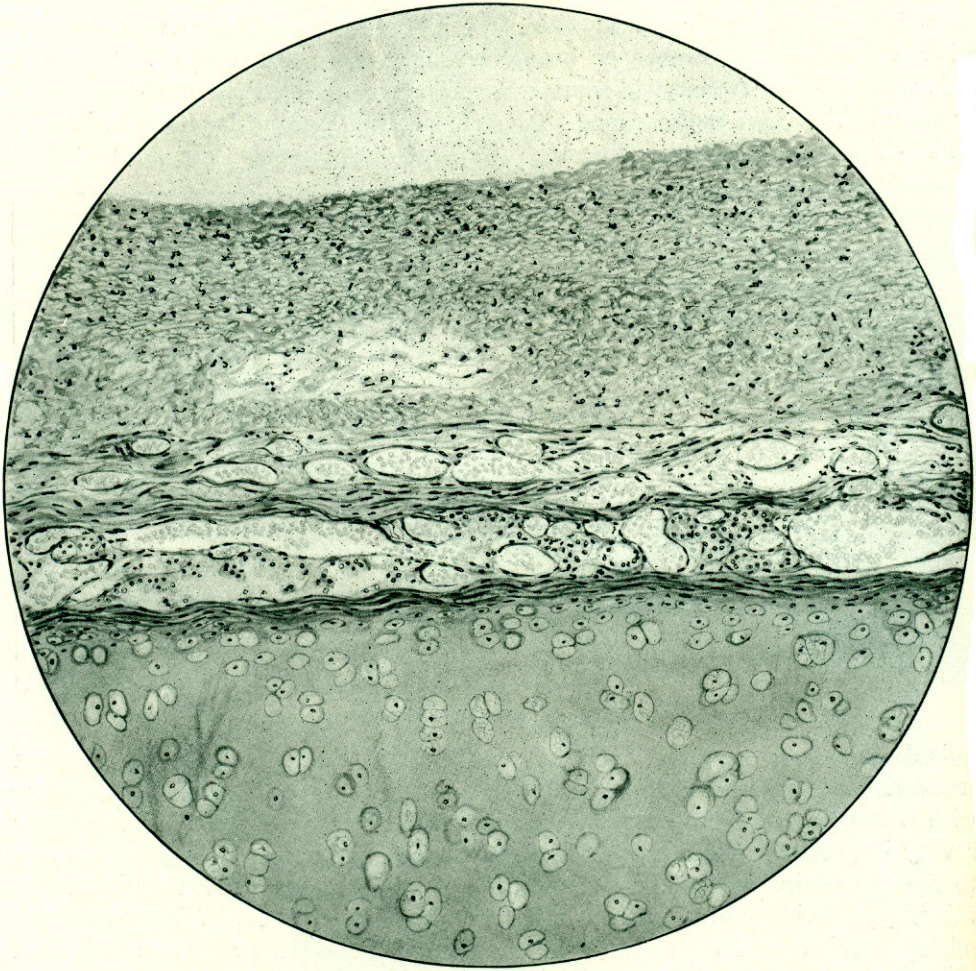

FIG. 13.—Case 22. Mustard-gas burn, 5 days' duration. Deep necrosis of tracheal mucosa