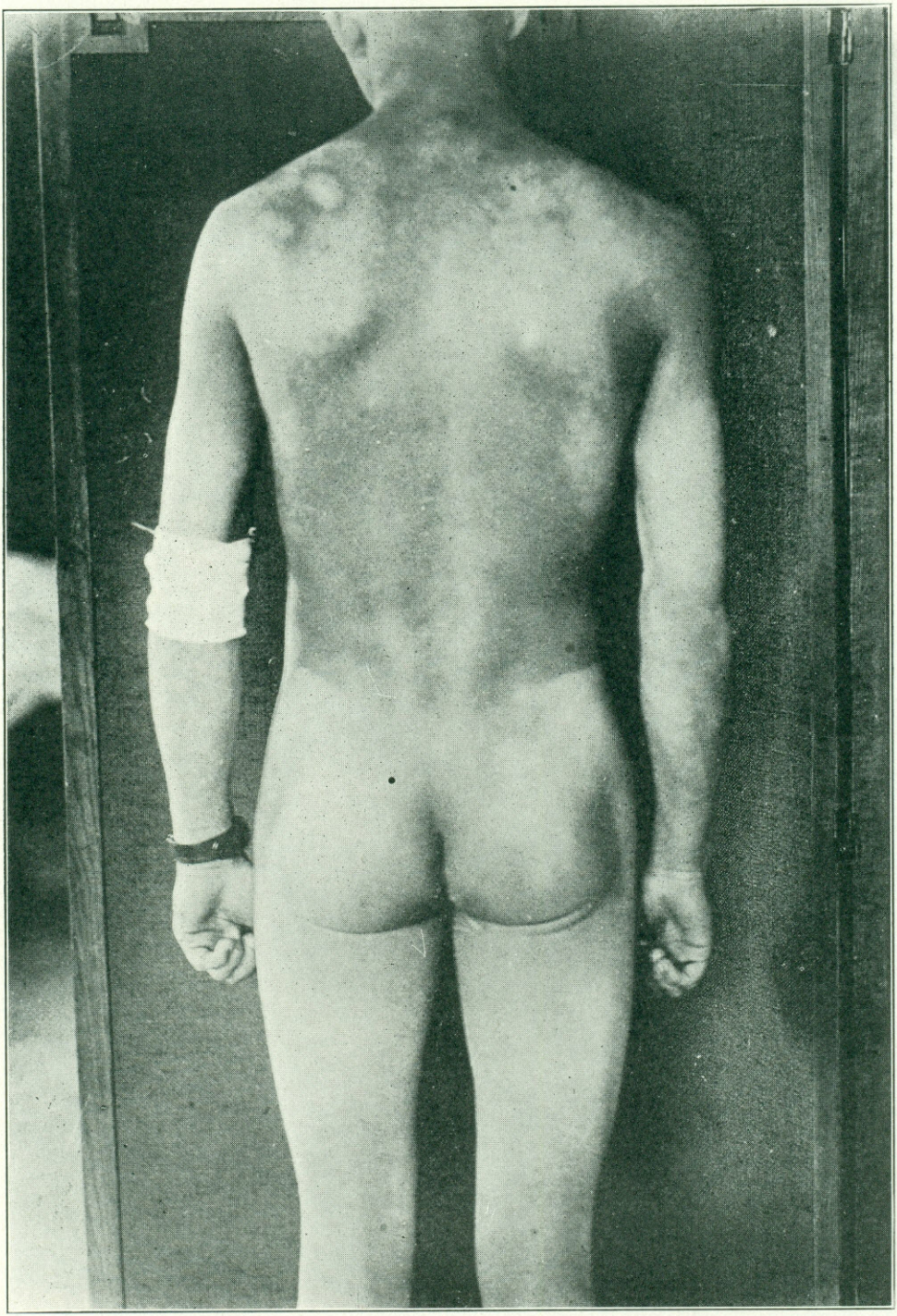

FIG. 141.—Rear view of same patient shown in Figure 140