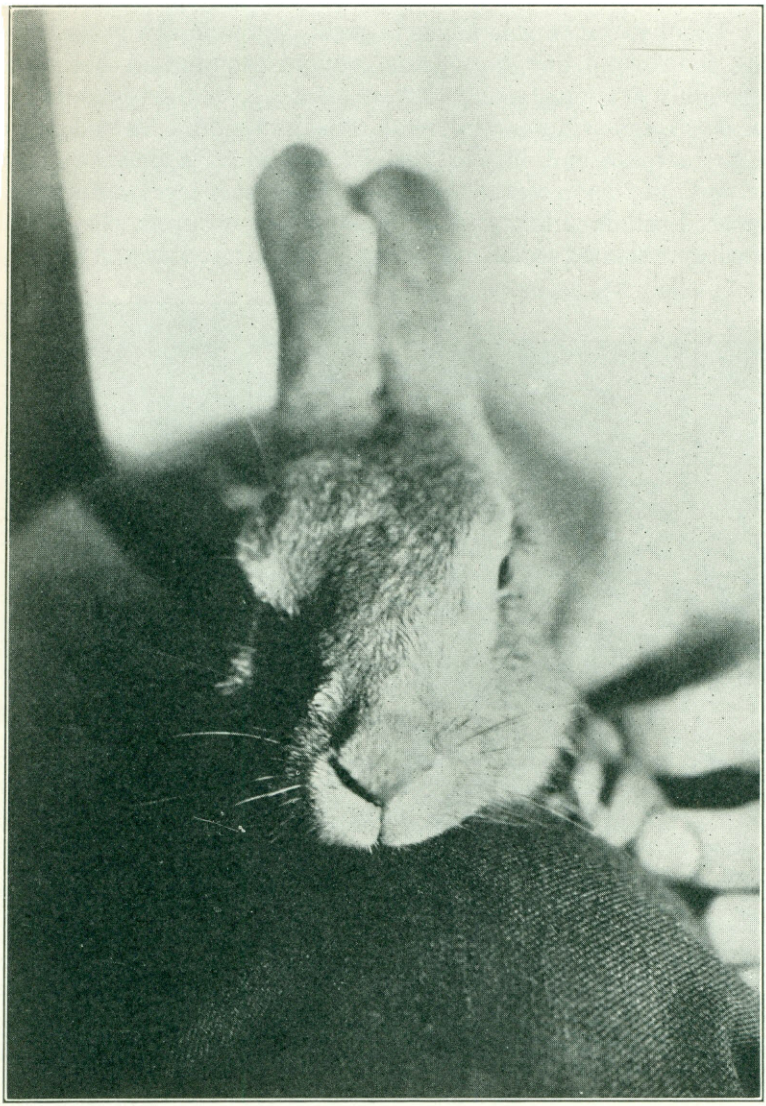

FIG. 149.—Twenty-four hours after direct application of standard droplet of dichlorethylsulphide to cornea of right eye. Marked edema of lids and surrounding subcutaneous tissue