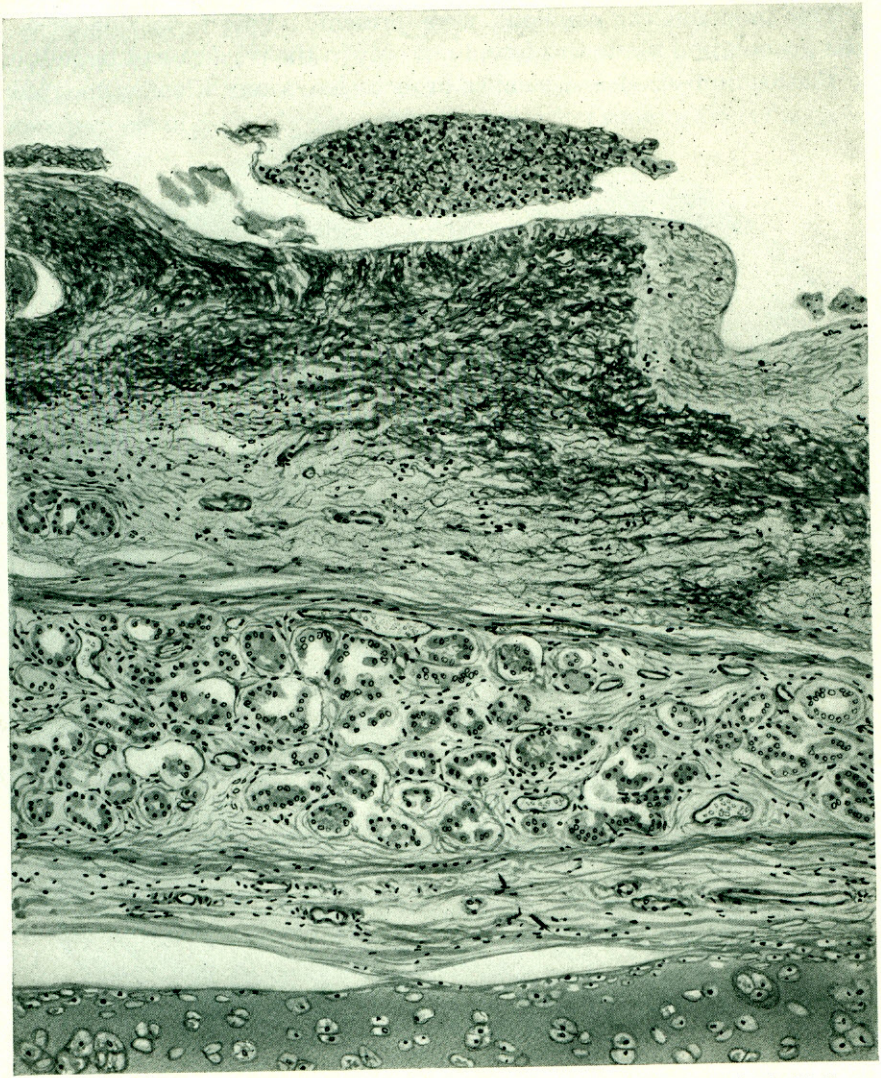

FIG. 14.—Case 21. Mustard-gas burn, 5 days' duration. Necrosis and exfoliation of trachea lepithelium exposing basement membrane. Fibrinous edema of submucosa