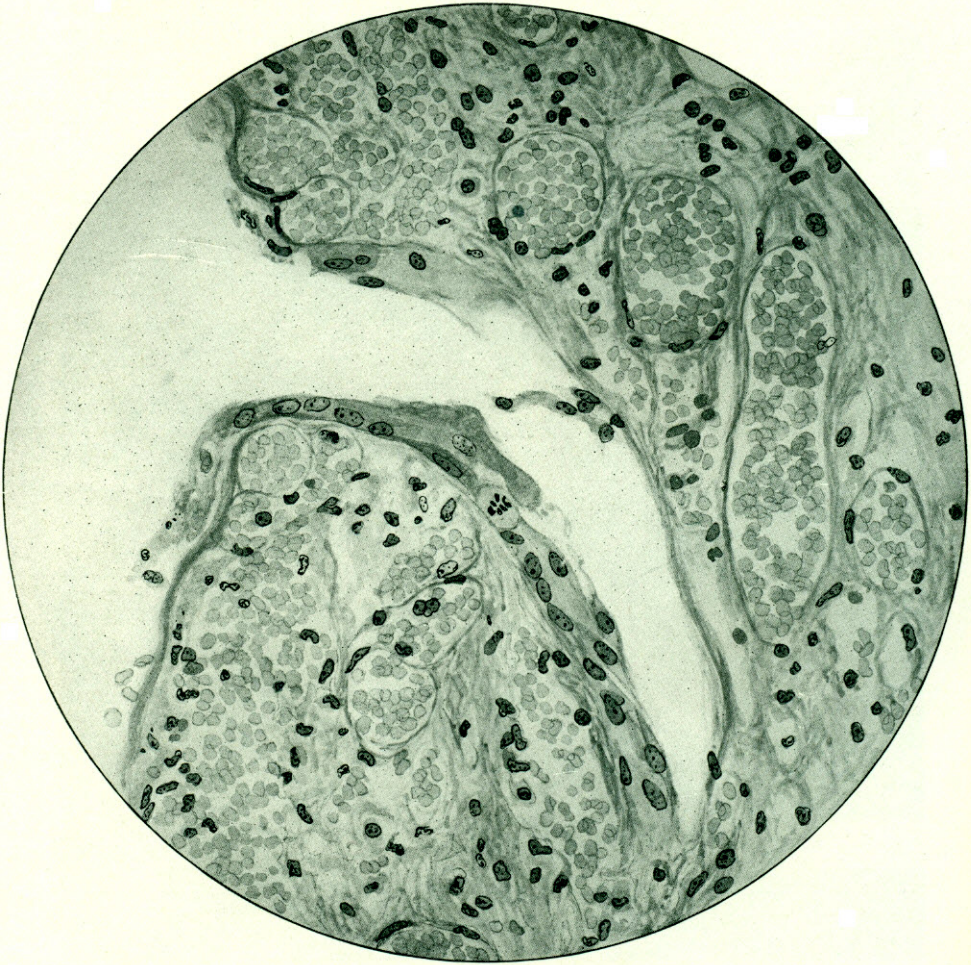

FIG. 15.—Case 61. Mustard-gas burn, 9 days' duration. Epithelial regeneration of trachea, proceeding from the mucous ducts