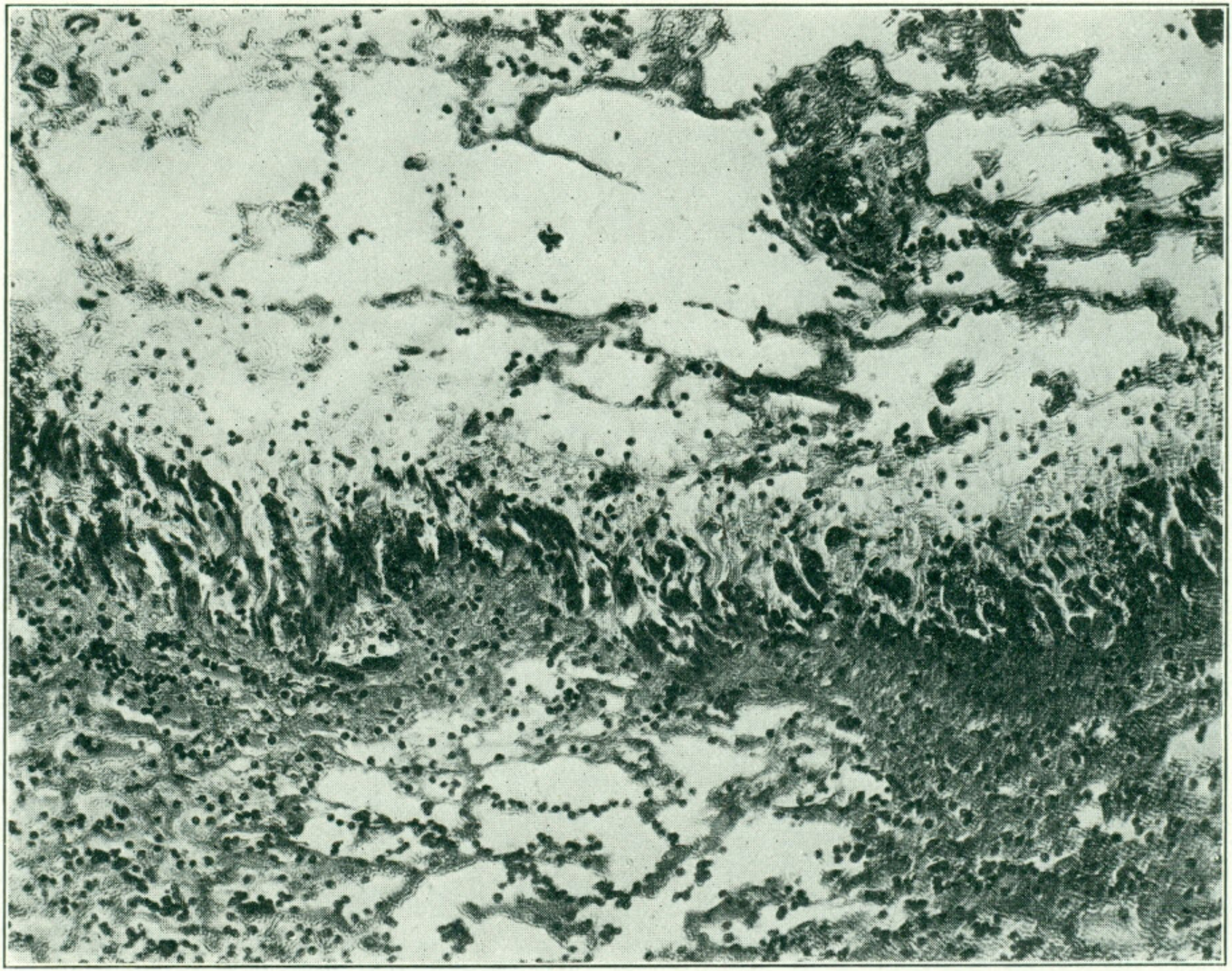

FIG. 169.—Section from the same region as in Figure 168, but taken deeper down, showing the extreme edema and liquefaction necrosis, below the narrow band of the sphincter orbicularis