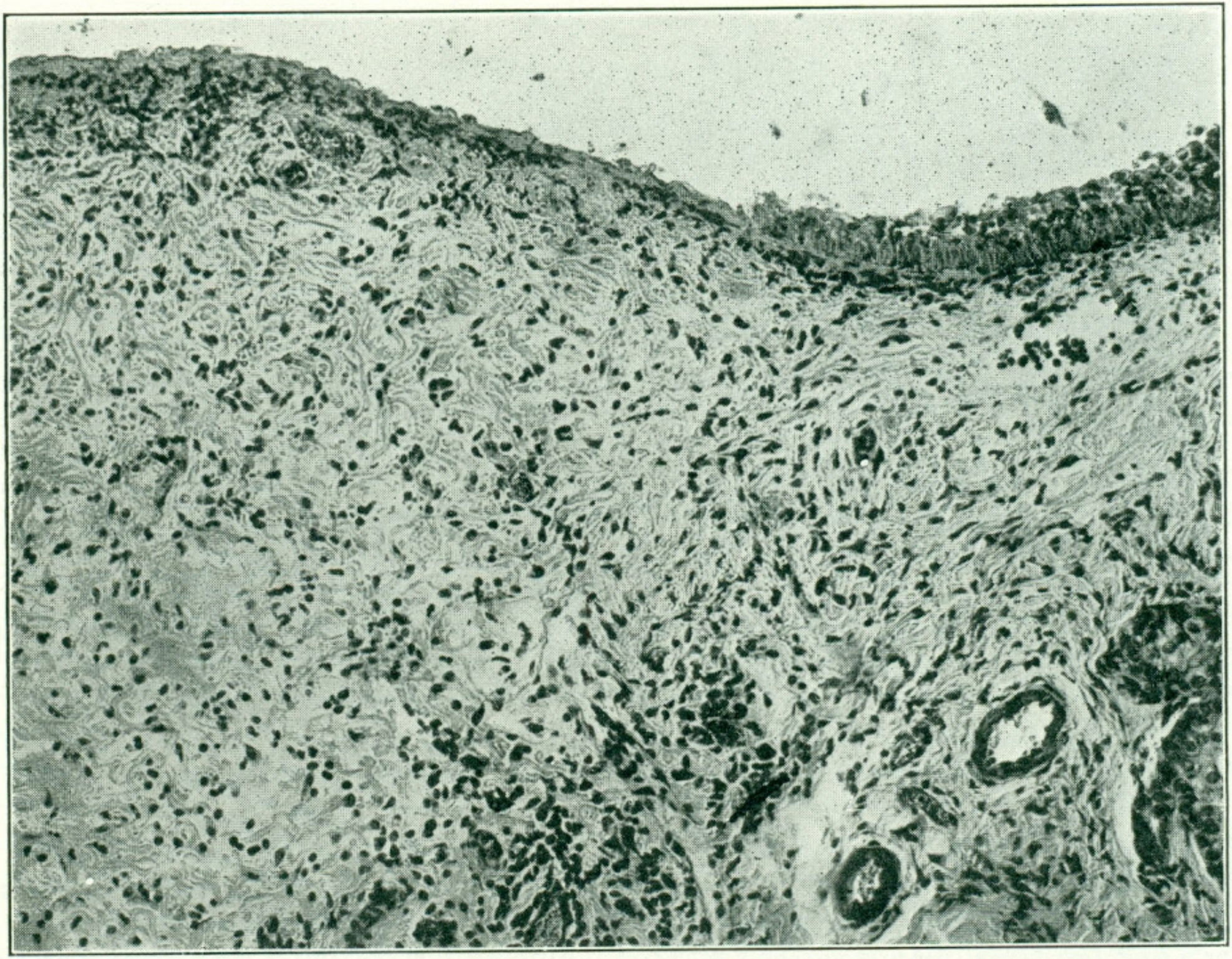

FIG. 173.—Section of upper lid at palpebra margin four days after direct application of standard droplet of dichlorethylsulphide. Advanced ulceration beginning repair