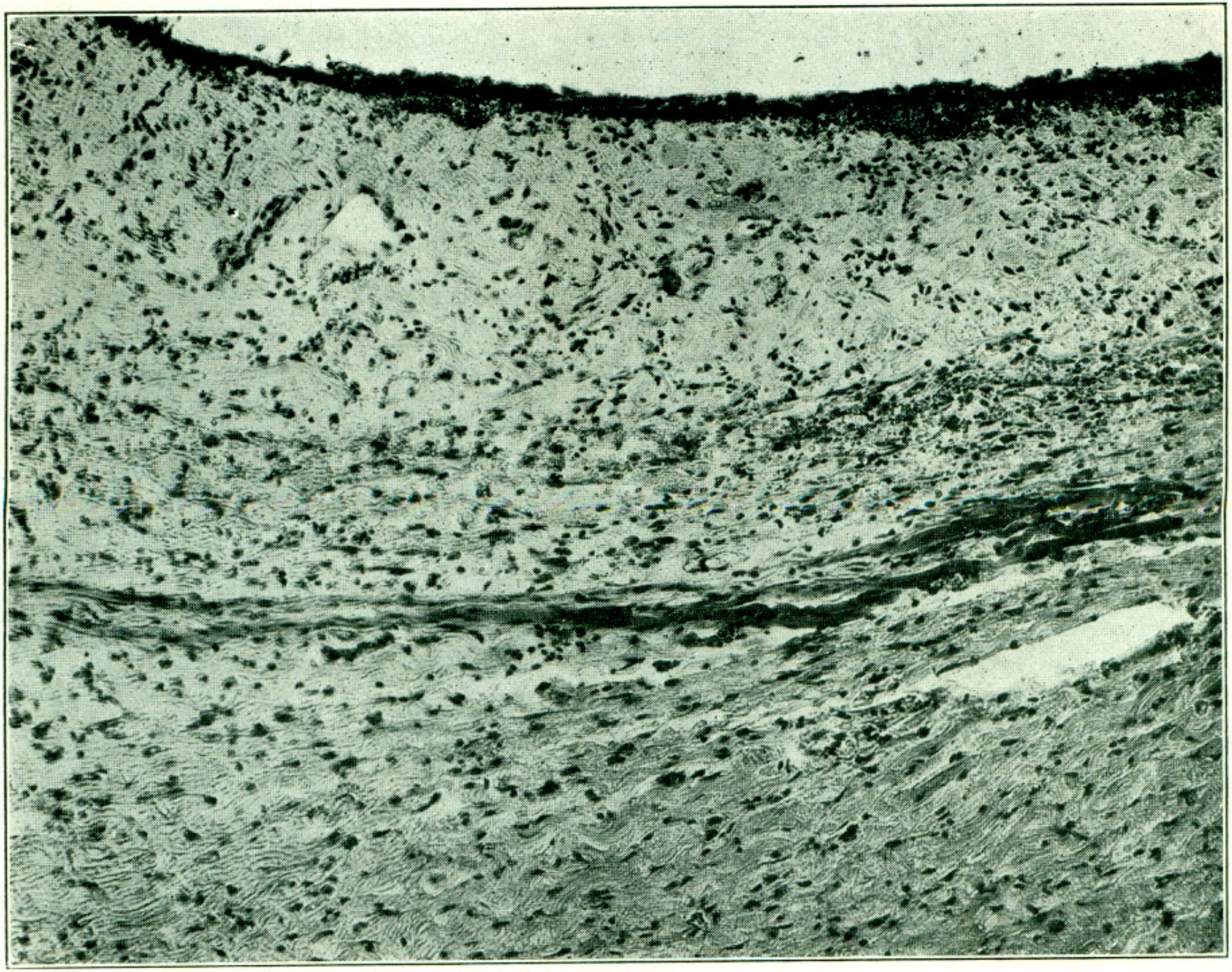

FIG. 174.—Section of same lid near fornix. Regeneration of the conjunctival epithelium. Disappearance of the edema and advancing cicatrization of the subconjunctival tissues