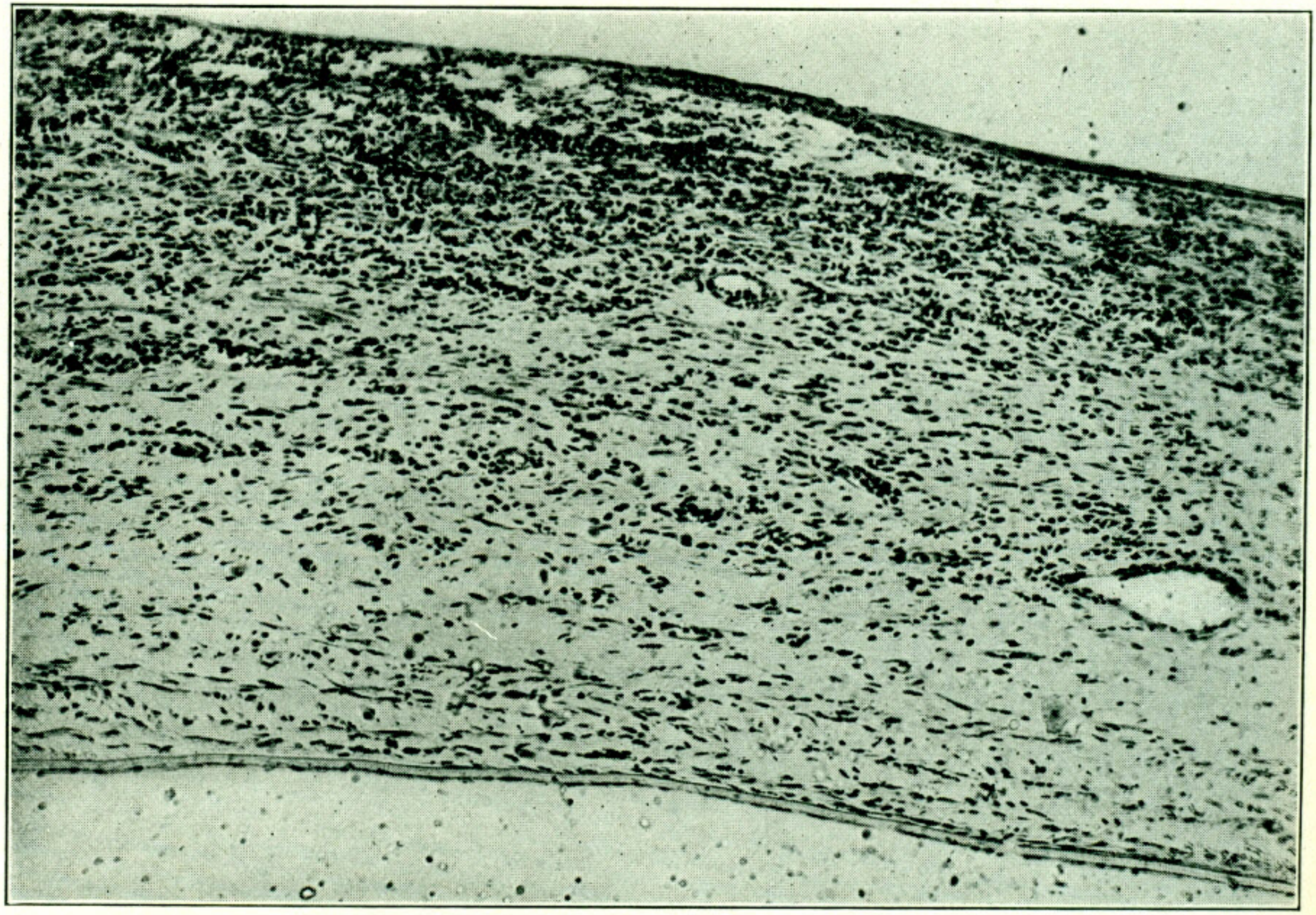

FIG. 177.—Sclerocorneal junction of same eye as in Figure 176, four weeks after application of standard droplet, showing vascularization and repair proceeding from the sclera