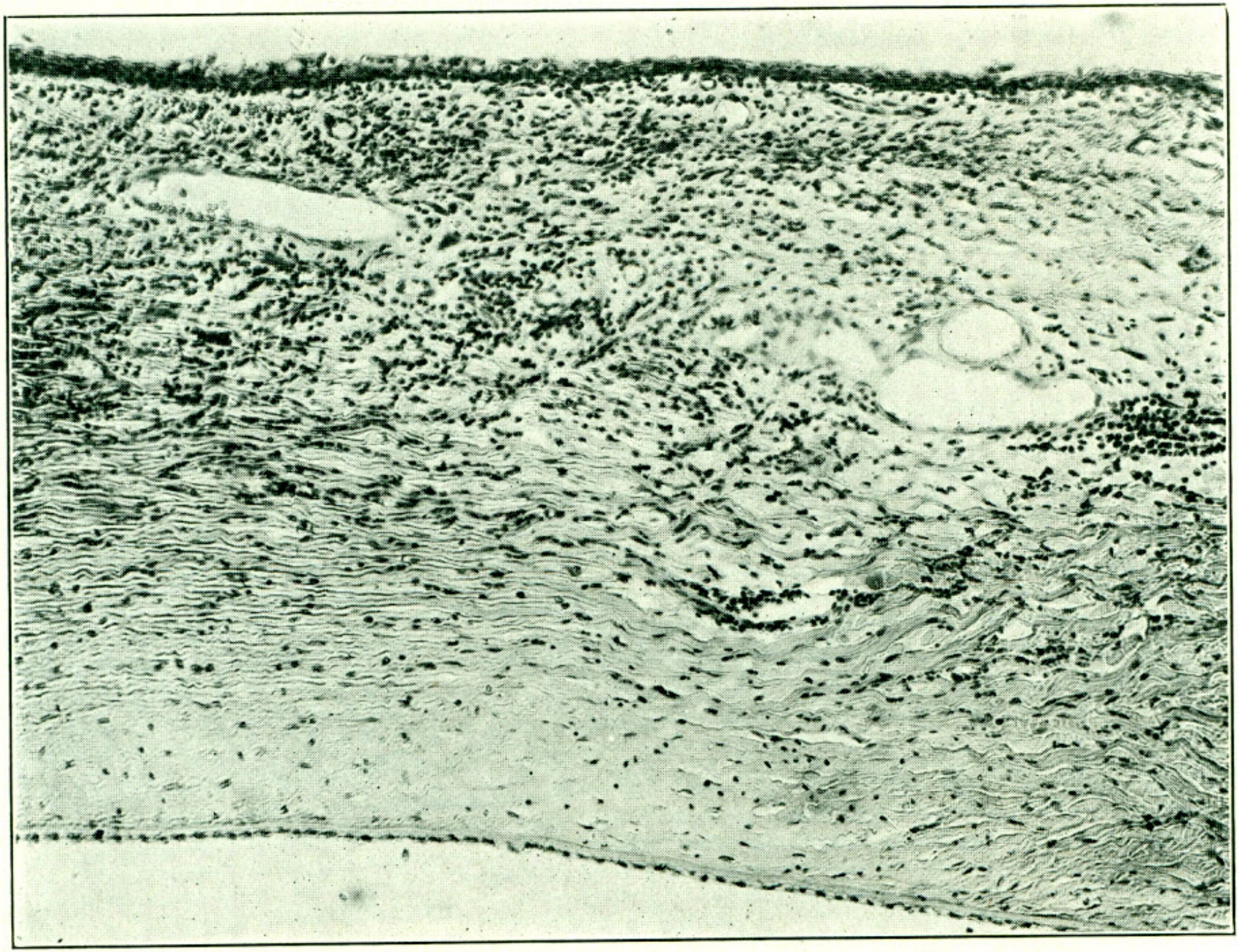

FIG. 178.—Section of corneal limbus 4 weeks after application of standard droplet of dichlorethylsulphide. Advancing repair into the cornea from the sclerocorneal junction