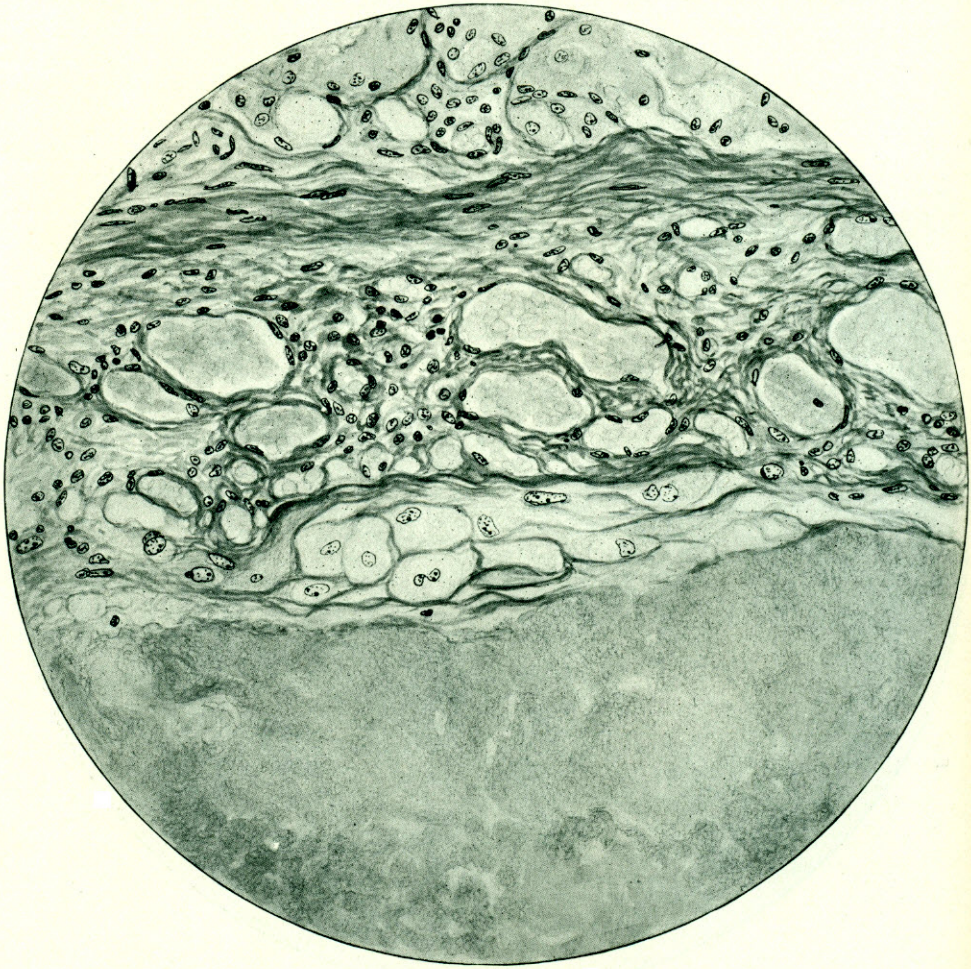

FIG. 17.—Case 24. Mustard-gas burn, 5 days' duration. Between the false membrane and the congested subepithelial tissue are interposed hydropic epithelial cells of the squamous type