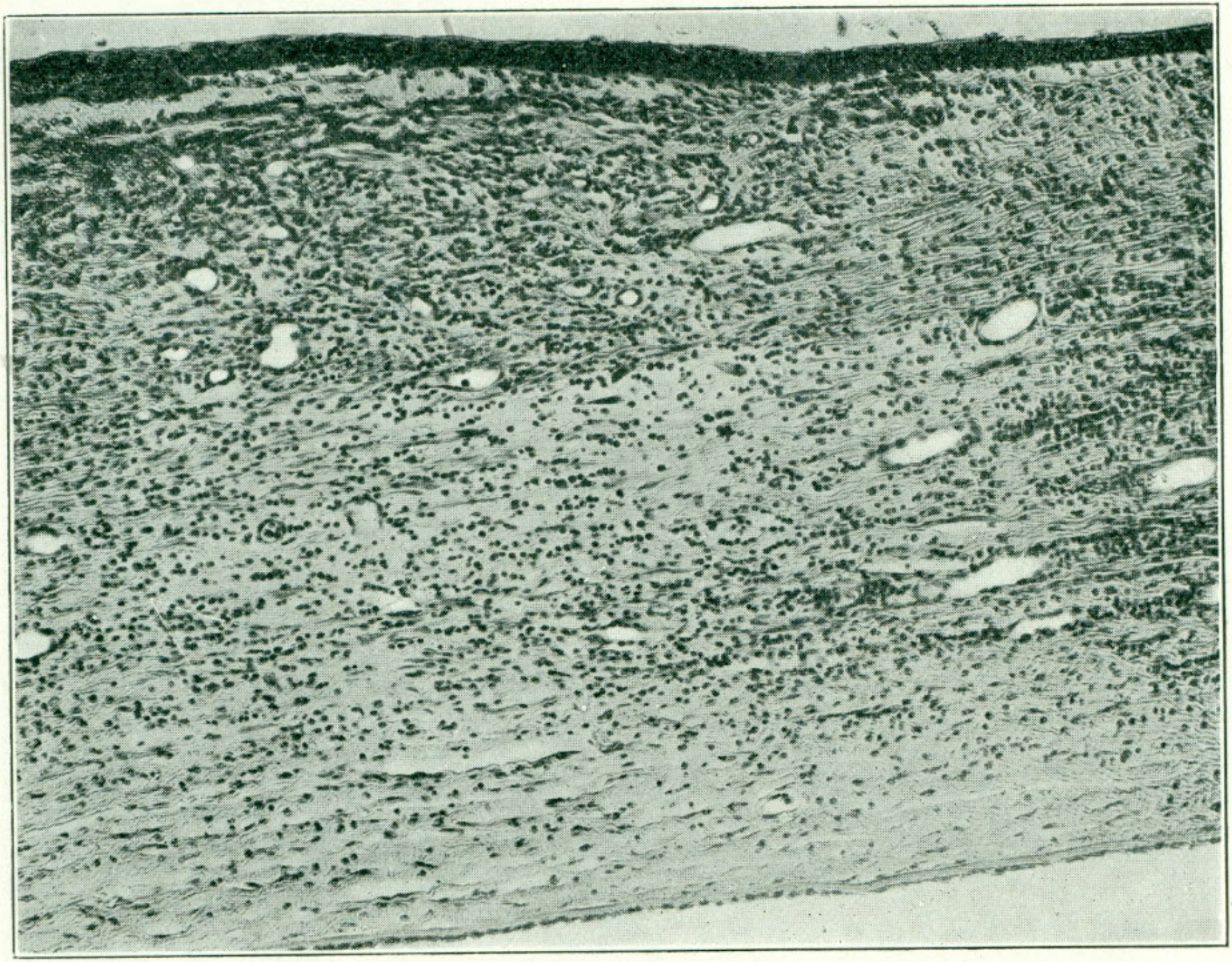

FIG. 182.—Section of corneal limbus from same eye as Figure 181, showing advanced cicatrization