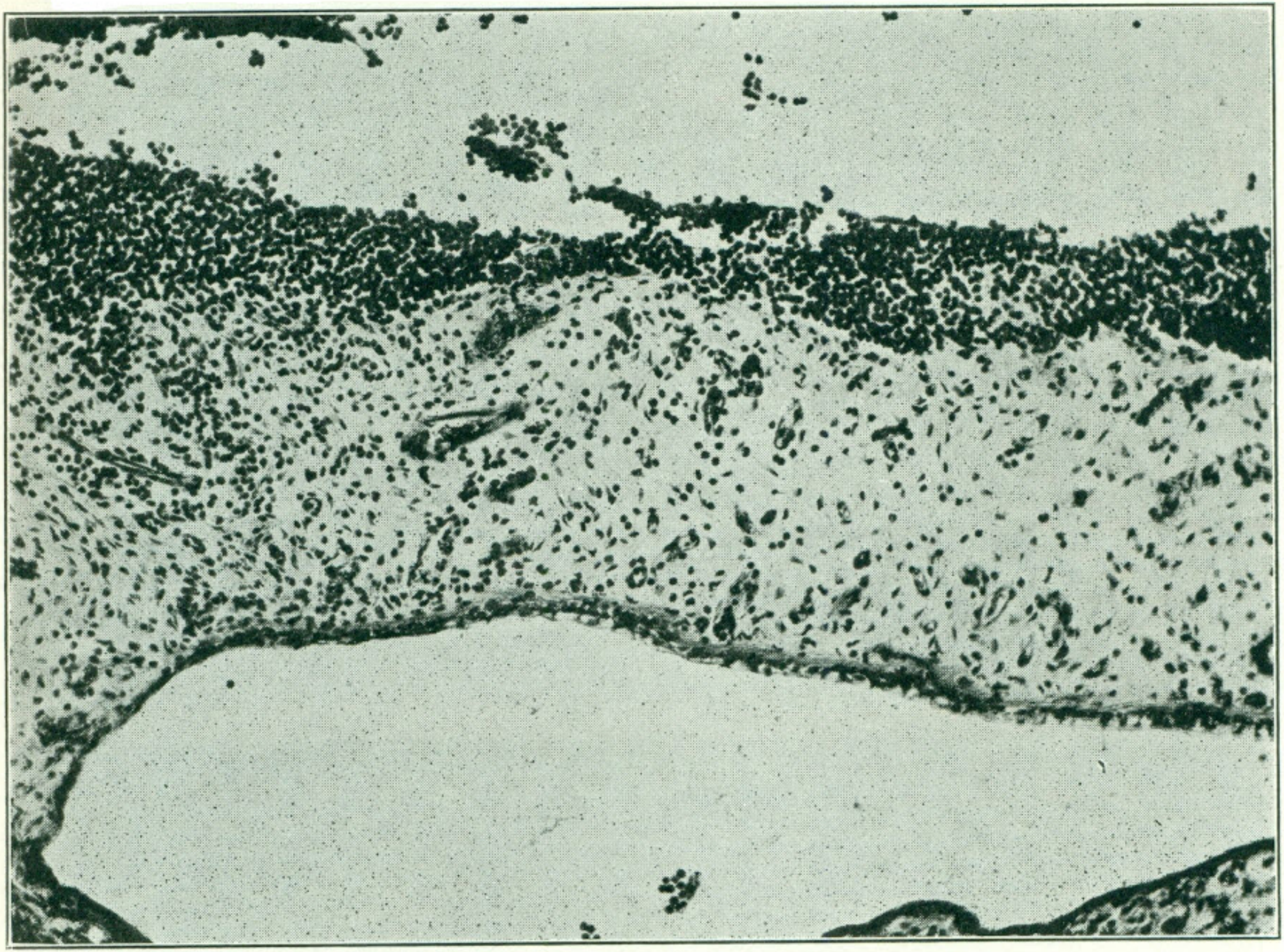

FIG. 184.—Iris of same eye as in Figure 183, showing congestion, edema, and polynuclear infiltration. Marked polynuclear exudate in the anterior chamber