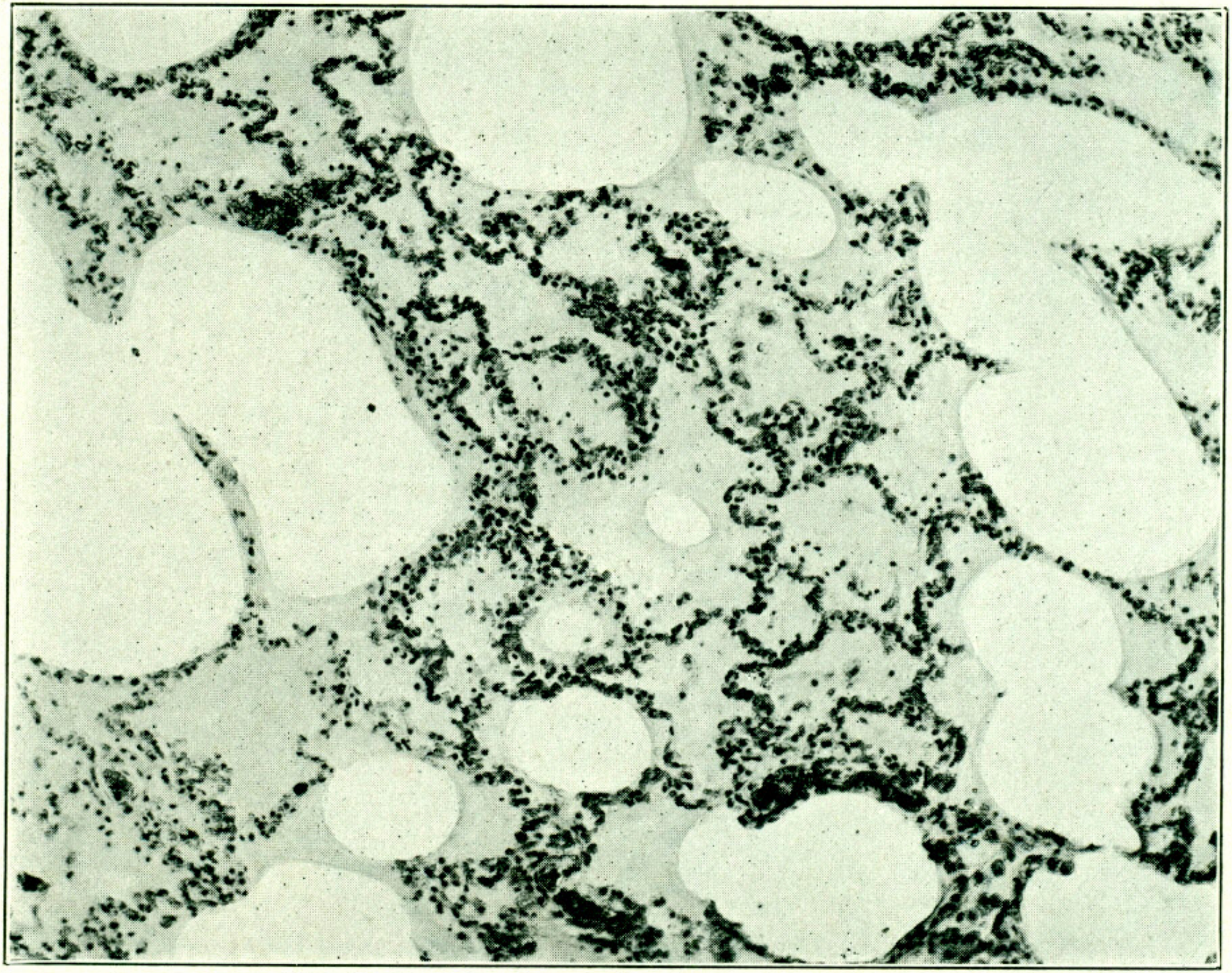

FIG. 194.—Lung of same rabbit as Figure 193. Acute congestion and edema