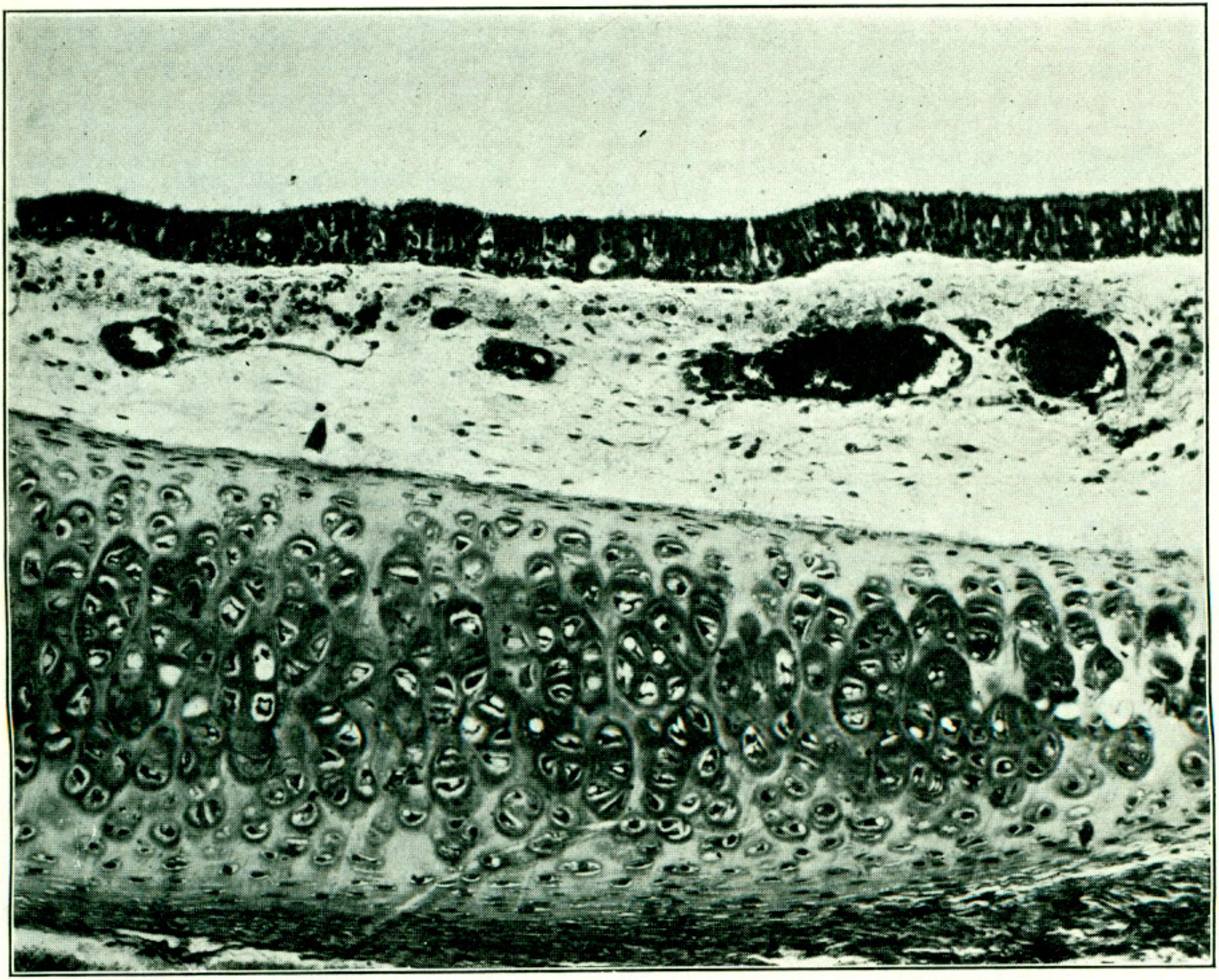

FIG. 196.—Section of tracheal wall of same rabbit as Figure 195. Similar changes in epithelium and submucosa