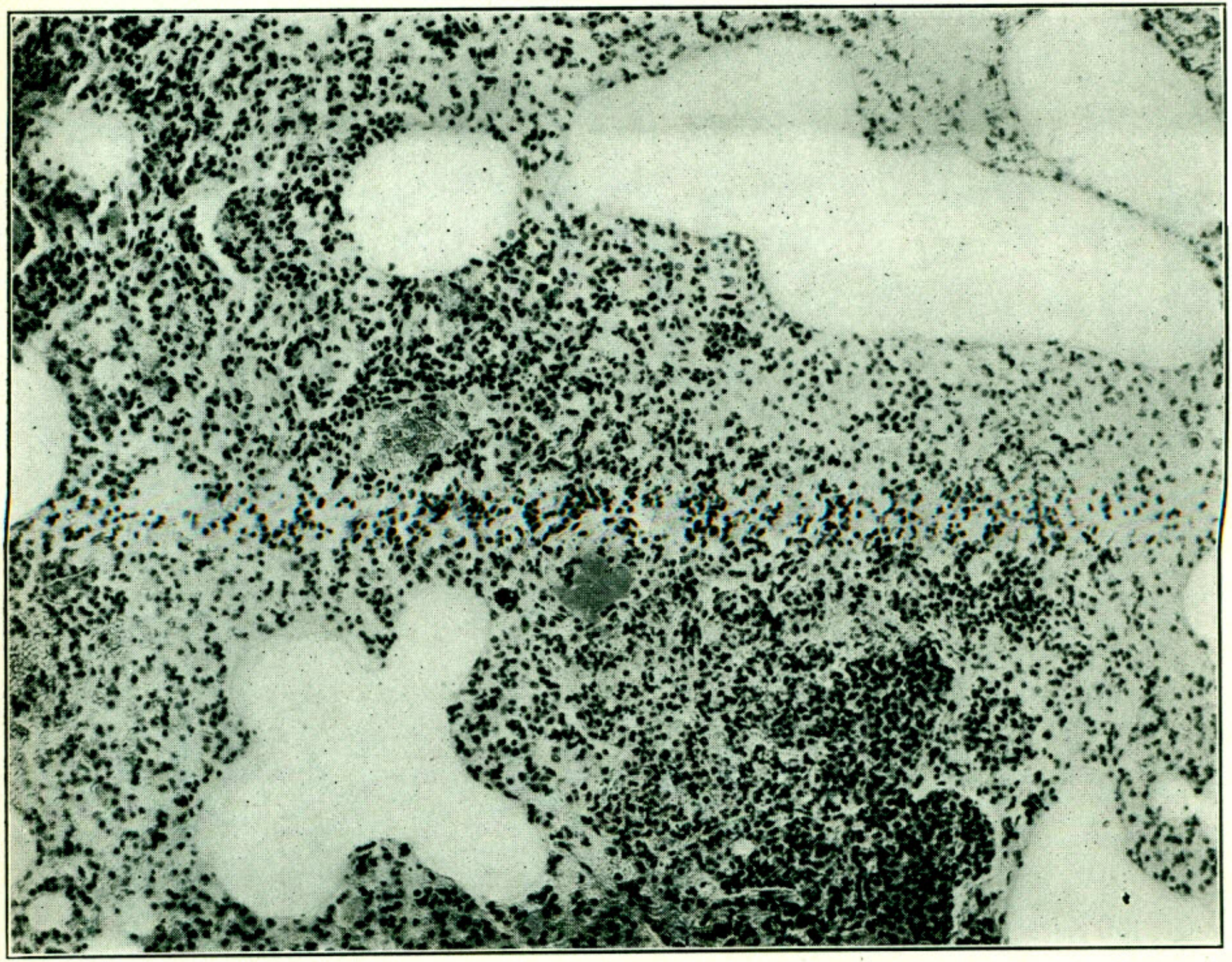

FIG. 198.—Section of lung from same case as Figure 197. Area of purulent bronchopneumonia with colony of cocci in the center of the field