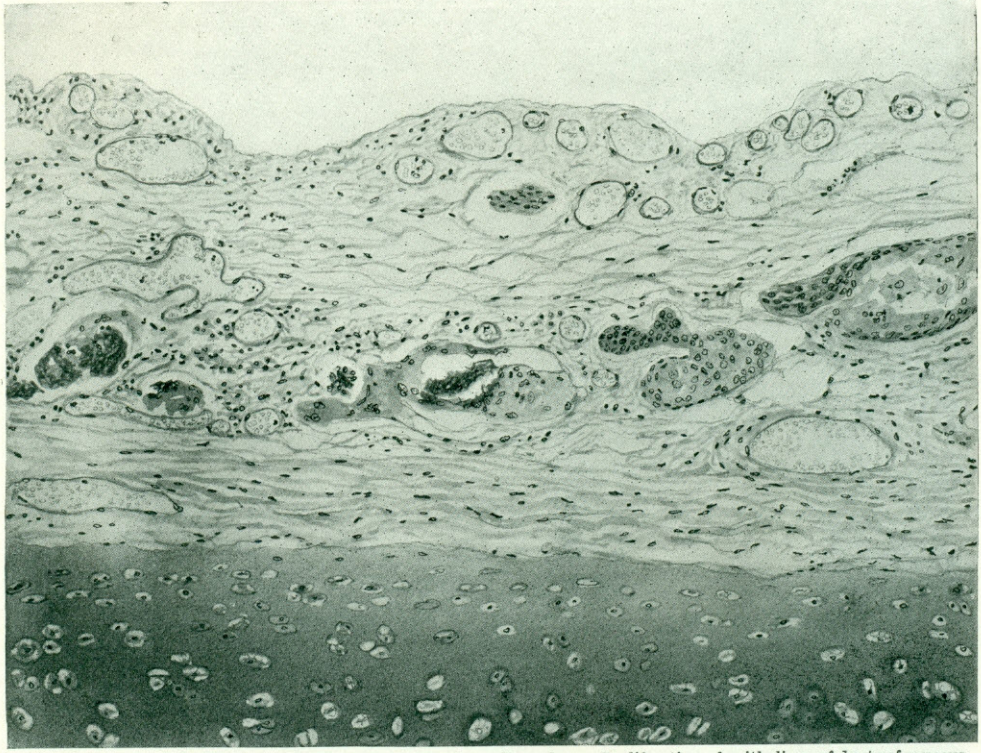

FIG. 19.—Case 86. Mustard-gas burn, 18 days' duration. Bronchus. Proliferation of epithelium of ducts of mucous glands