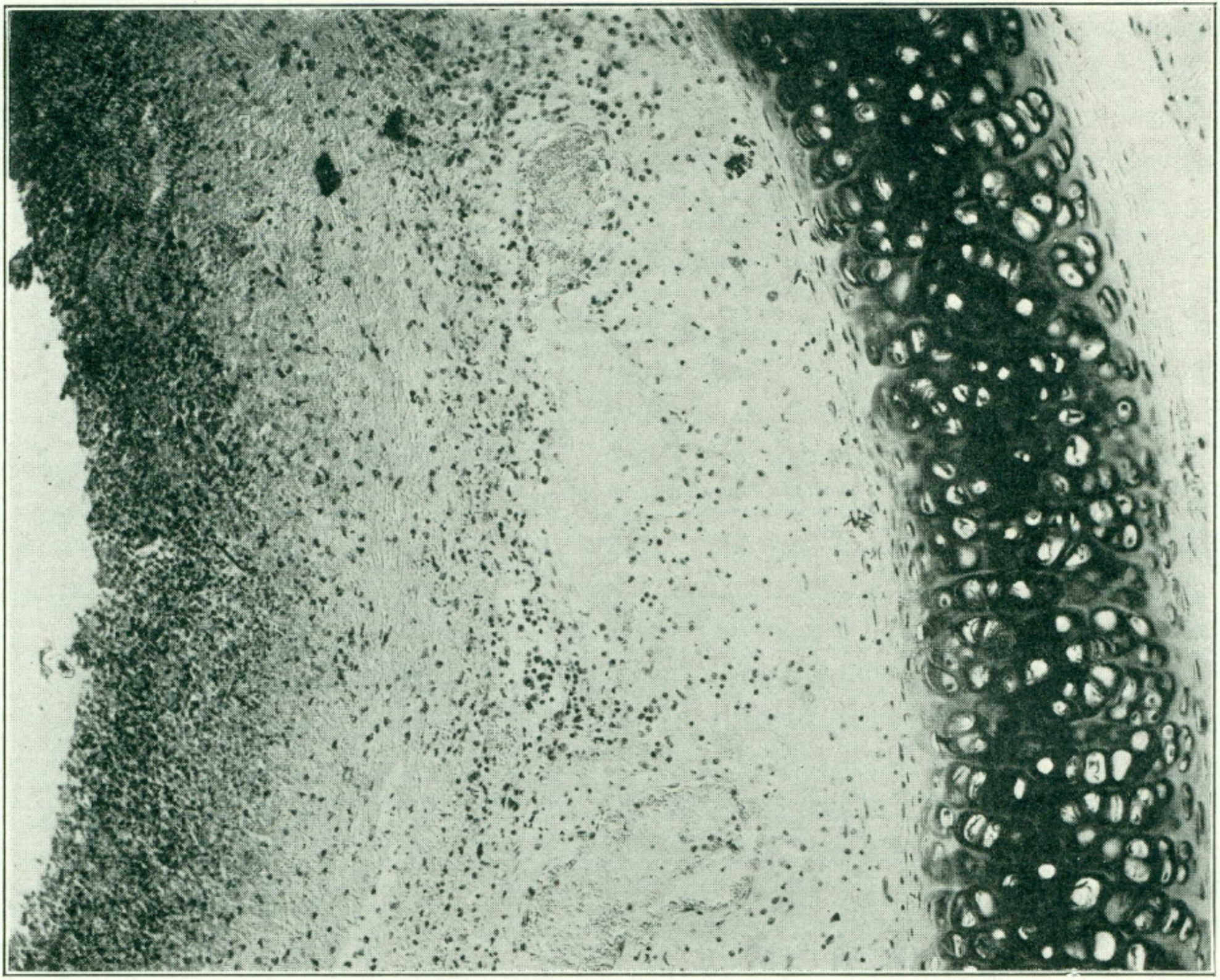

FIG. 200.—Same rabbit as Figure 199. Section of larynx showing diphtheritic ulcer