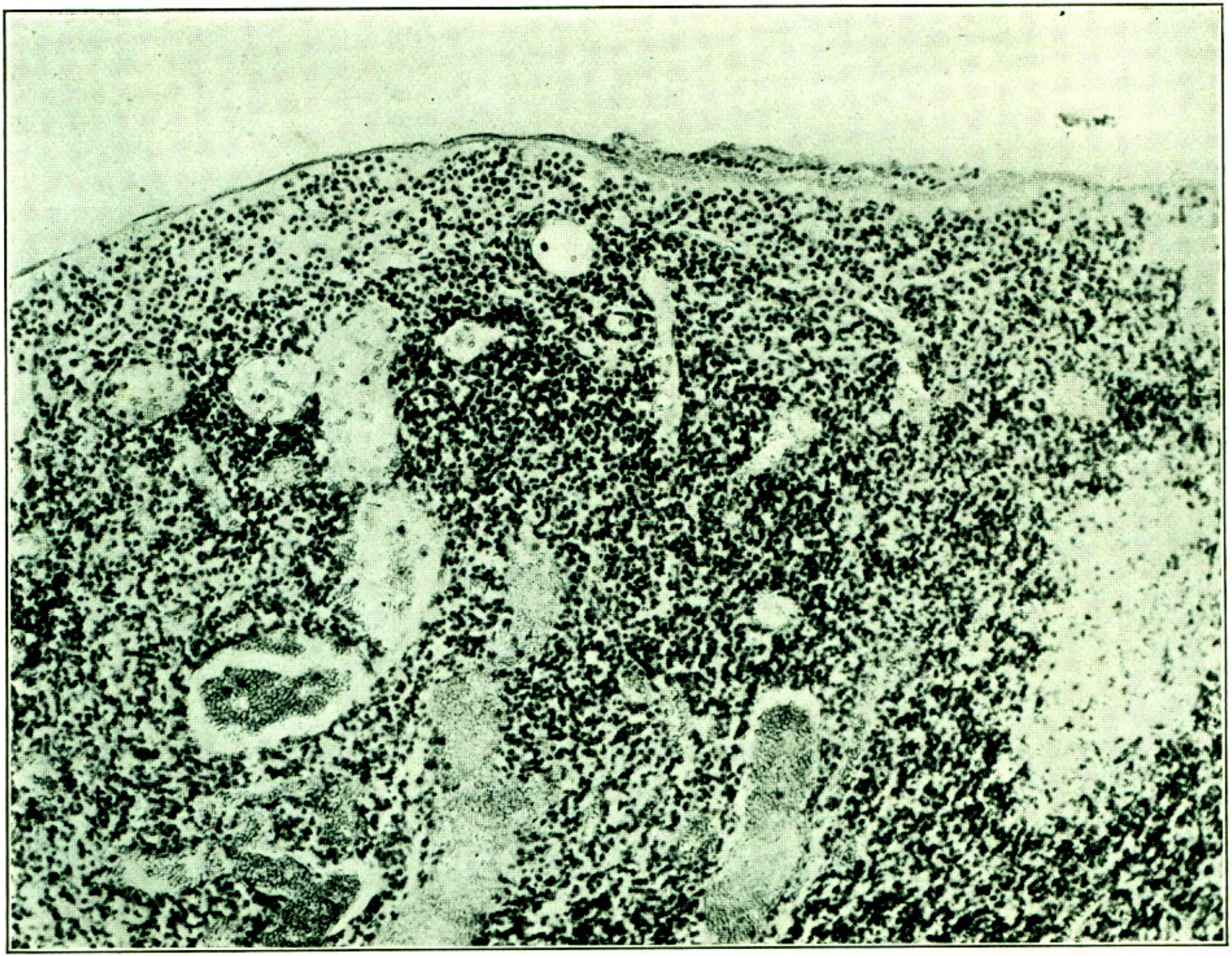

FIG. 202.—Case I, Private Ha. Mustard-gas lesion of dorsum of tongue. Base of ulcer from which the diphtheritic membrane has become detached