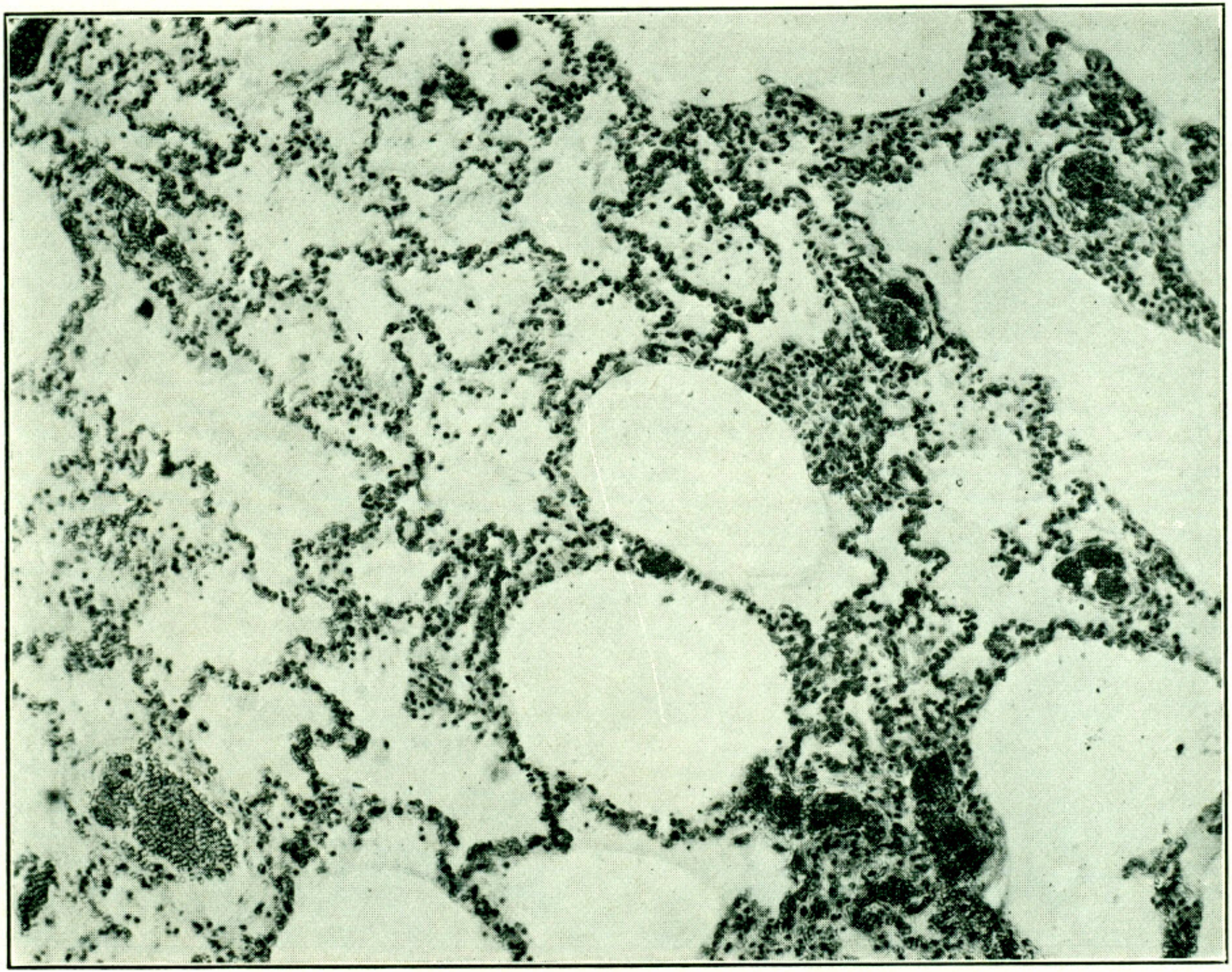

Fig. 205.—Case I, Private Ha. Section of upper lobe of lung. Congestion and edema. Acute emphysema