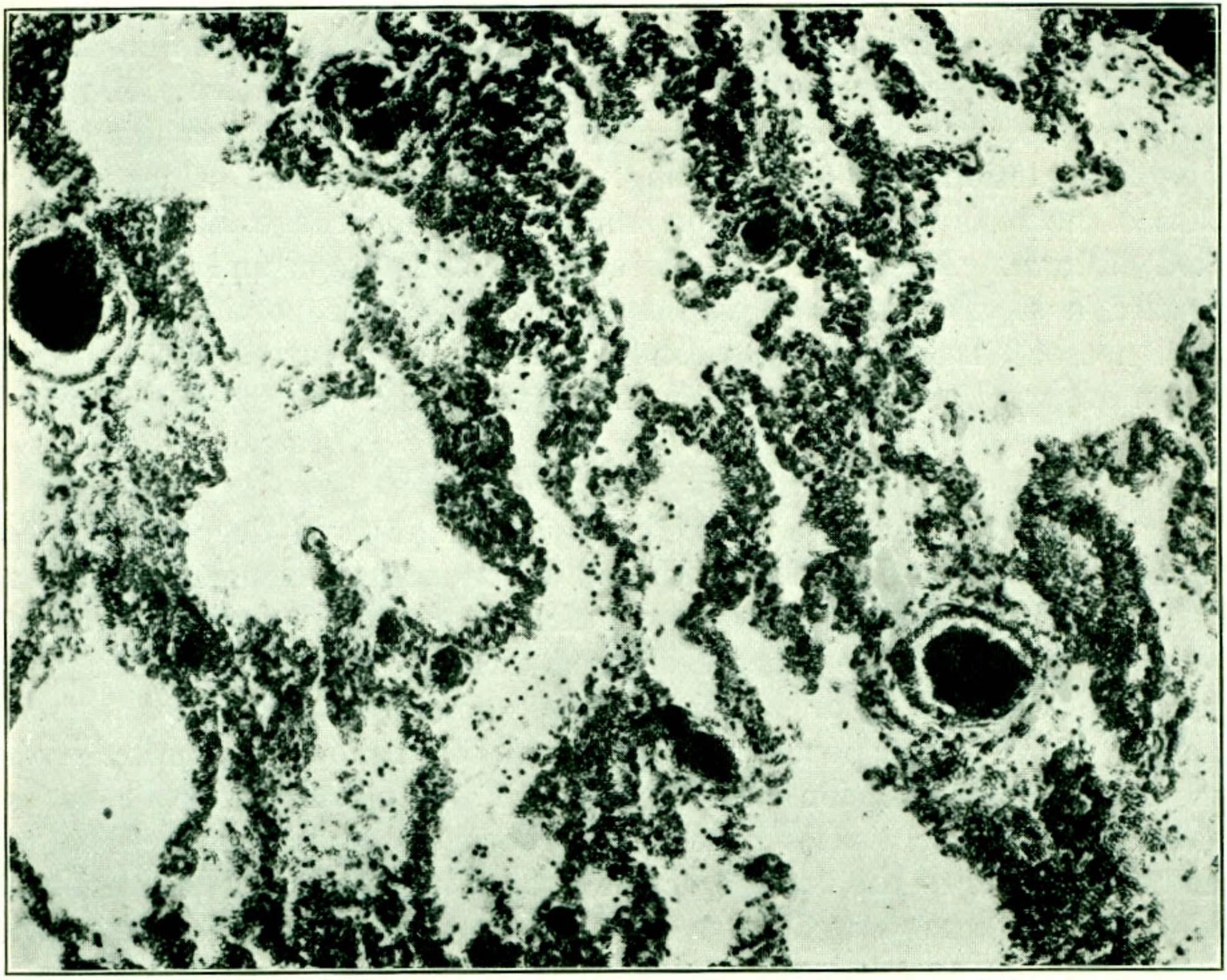

FIG. 206.—Case I, Private Ha. Section of lower lobe of lung. More intense congestion. Minute hemorrhages by diapedesis. Area of partial atelectasis, alternating with emphysematous areas. Edema