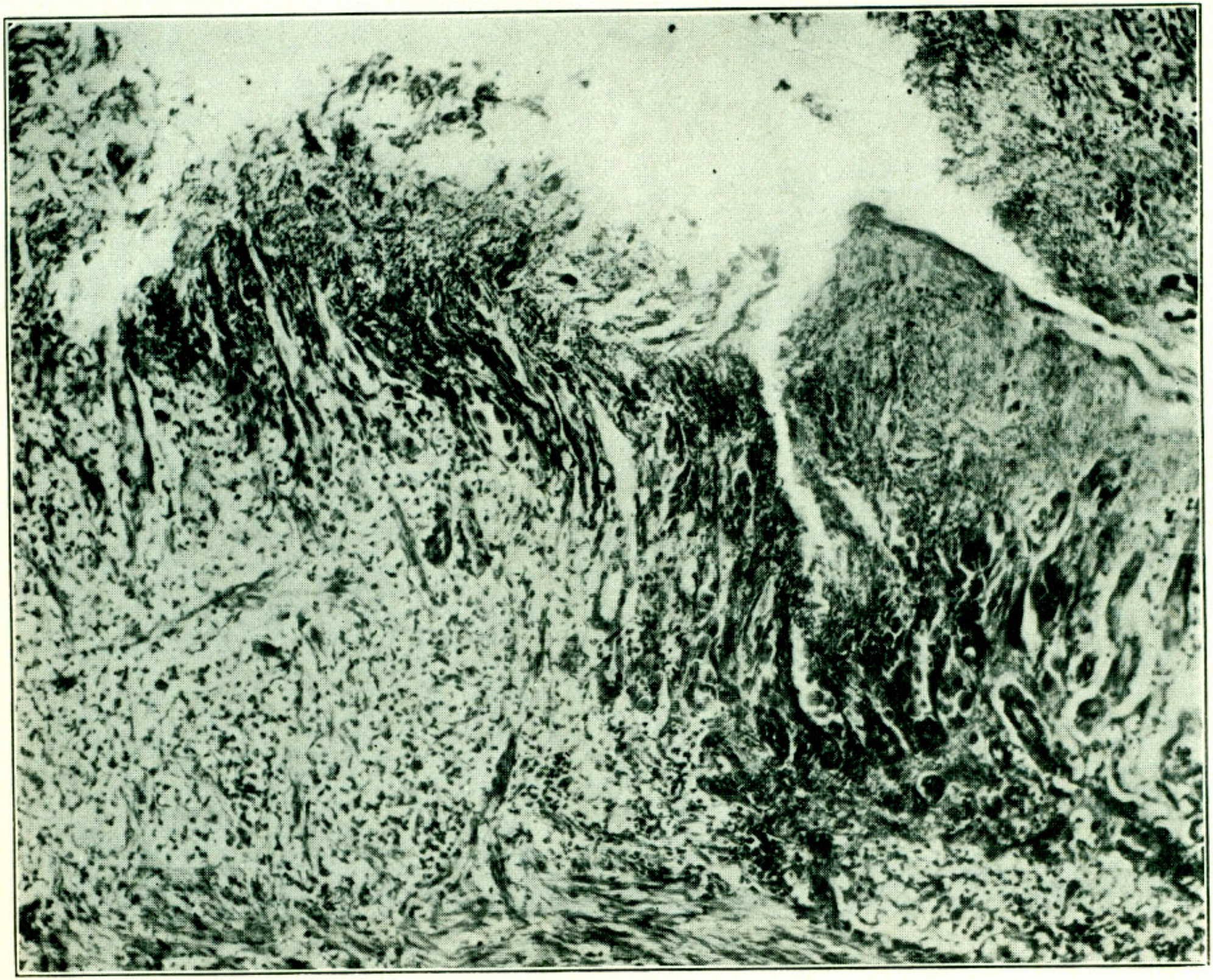

FIG. 207.—Dog. Received four minimis of dichlorethylsulphide on meat. Died five days afterwards. Small mustard-gas eschar in stomach mucosa. Early fibroblastic proliferation