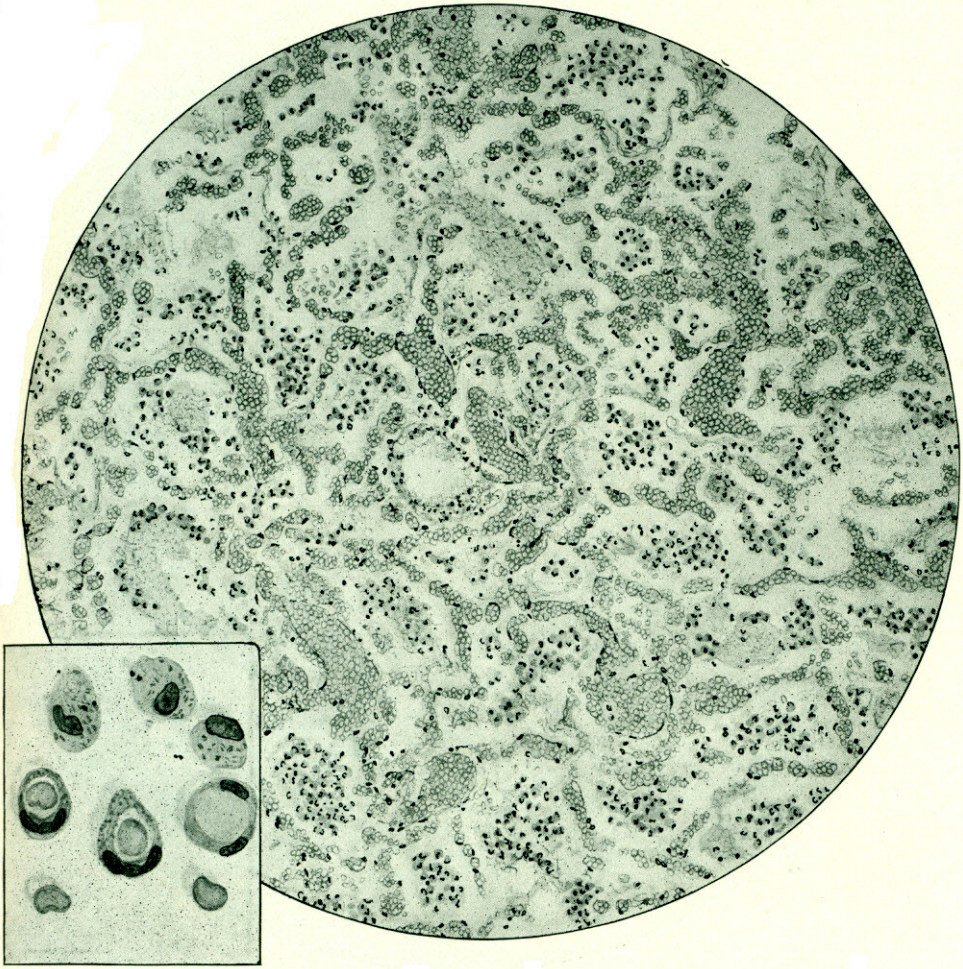

FIG. 20.—Case 28. Mustard-gas burn, 4–5 days' duration. Lung: Intense congestion, hemorrhagic edema, aplastic exudate. The lecuocytes are filled with minute Gram-negative bacilli