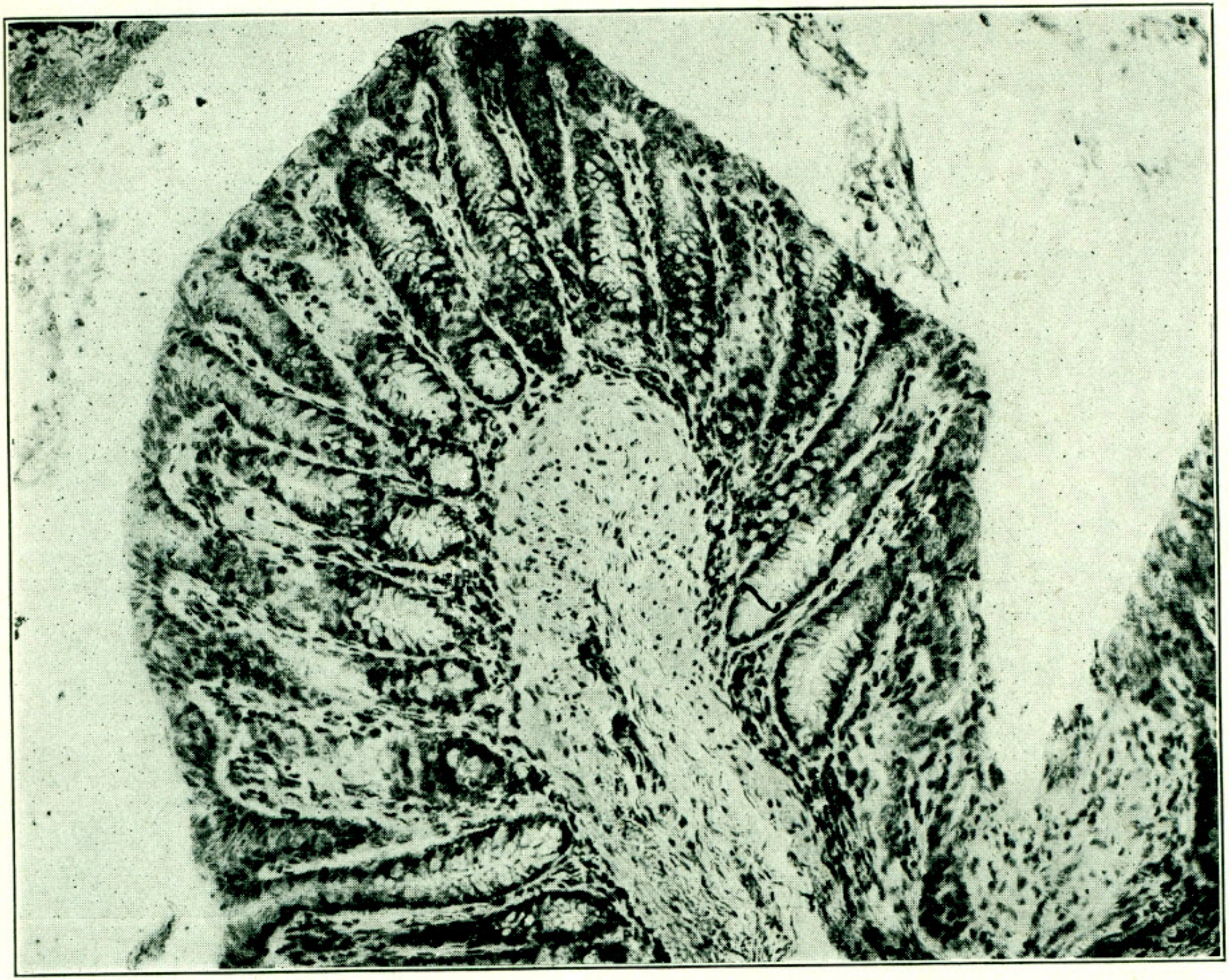

FIG. 212.—Rabbit. Received subcutaneous injection of .045 c. c. of dichlorethylsulphide. Died on third day during mild diarrhea. General mucoid degeneration