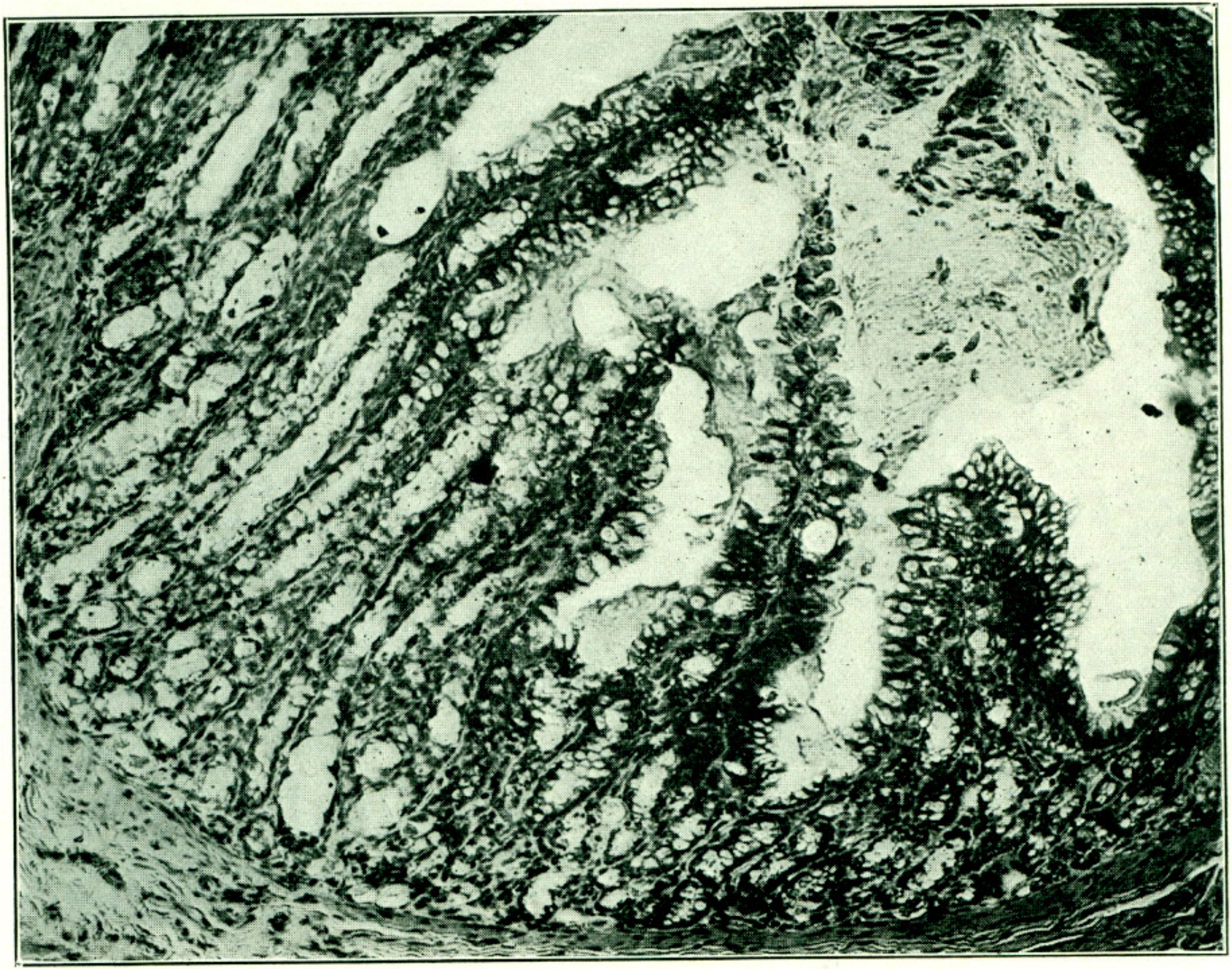

FIG. 214.—Same rabbit as in Figure 213. Extreme mucoid degeneration. Catarrhal enteritis. Mucous diarrhea