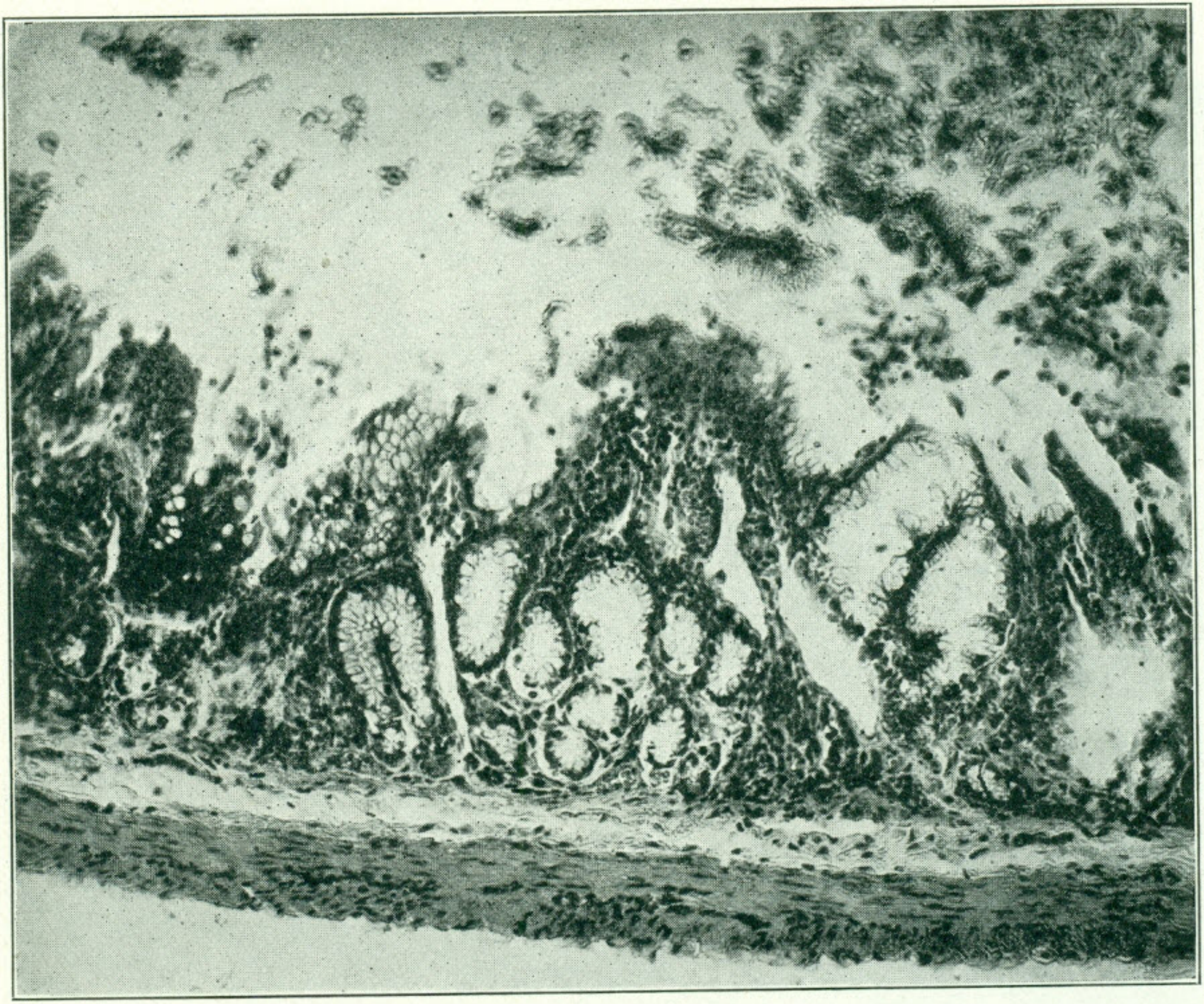

FIG. 215.—Section of cecal wall from same rabbit as in Figure 213. Marked catarrhal inflammation. Mucous diarrhea