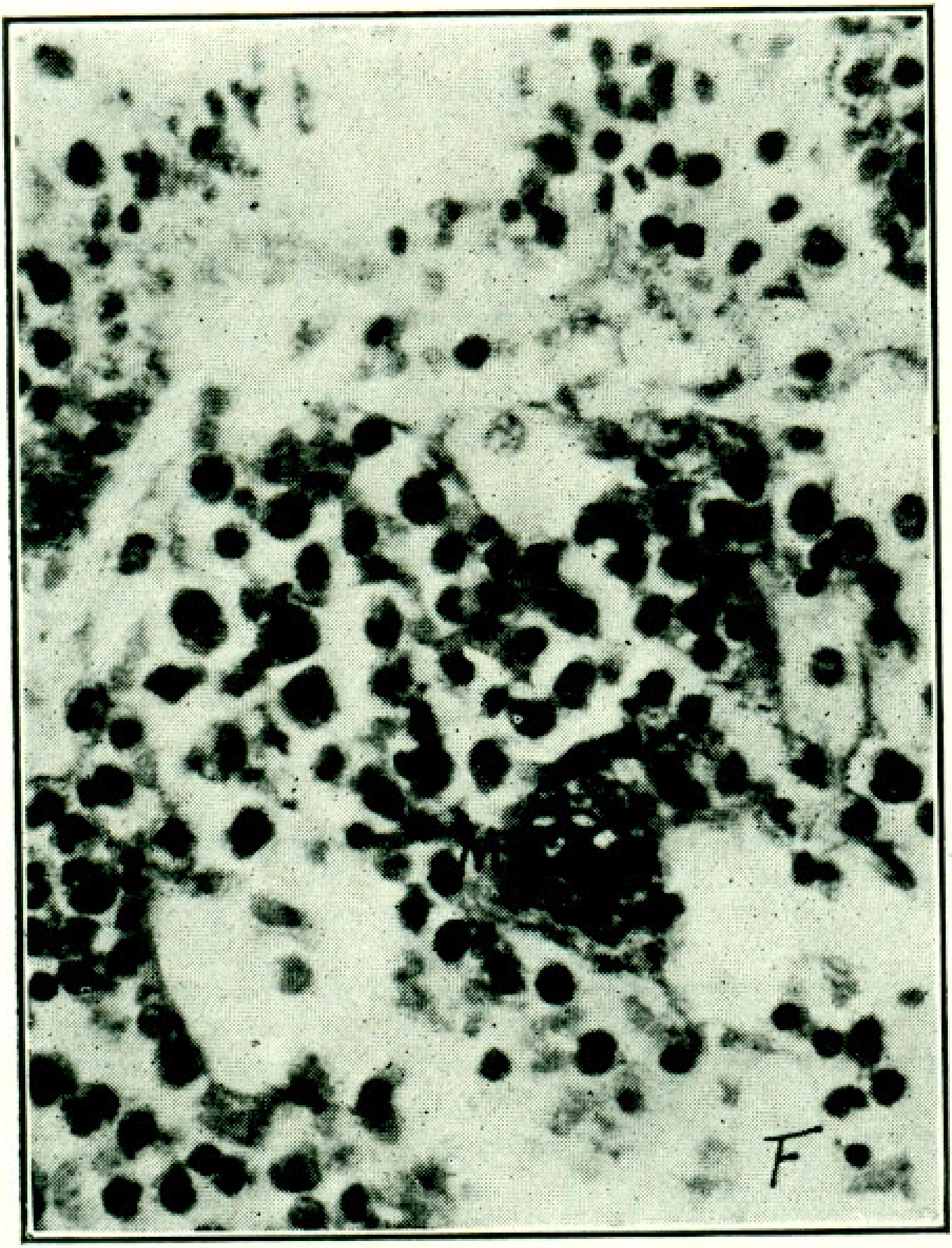

FIG. 232.—Normal rabbit. Bone marrow of femur. Megacaryocyte (M)