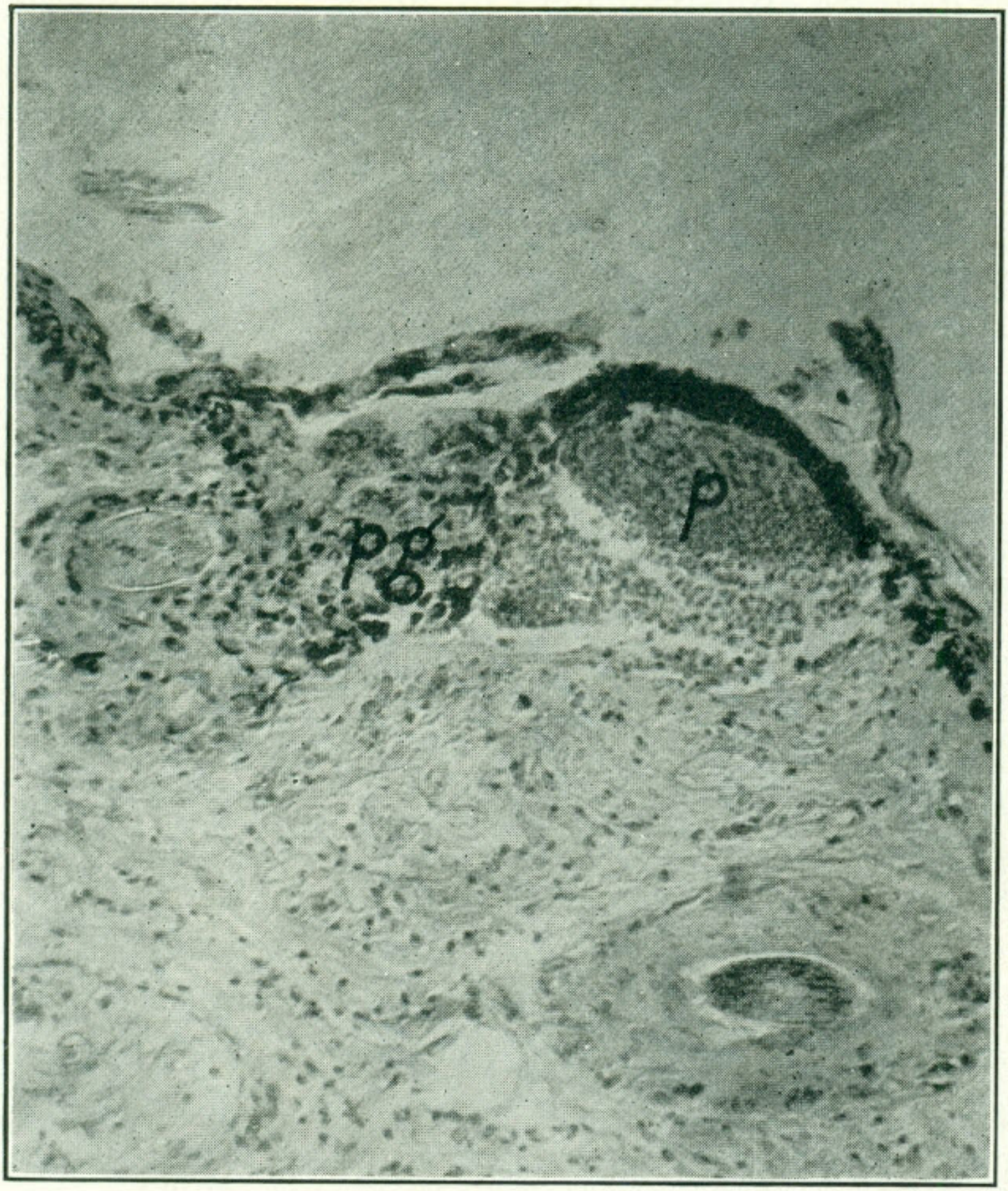


FIG. 235.—Dichlorethylsulphide, 98 hours after exposure. Superficial pustules (p) at margin of lesion. Increased pigmentation (pg) in adjacent epithelium. Leucocytic infiltration of corium