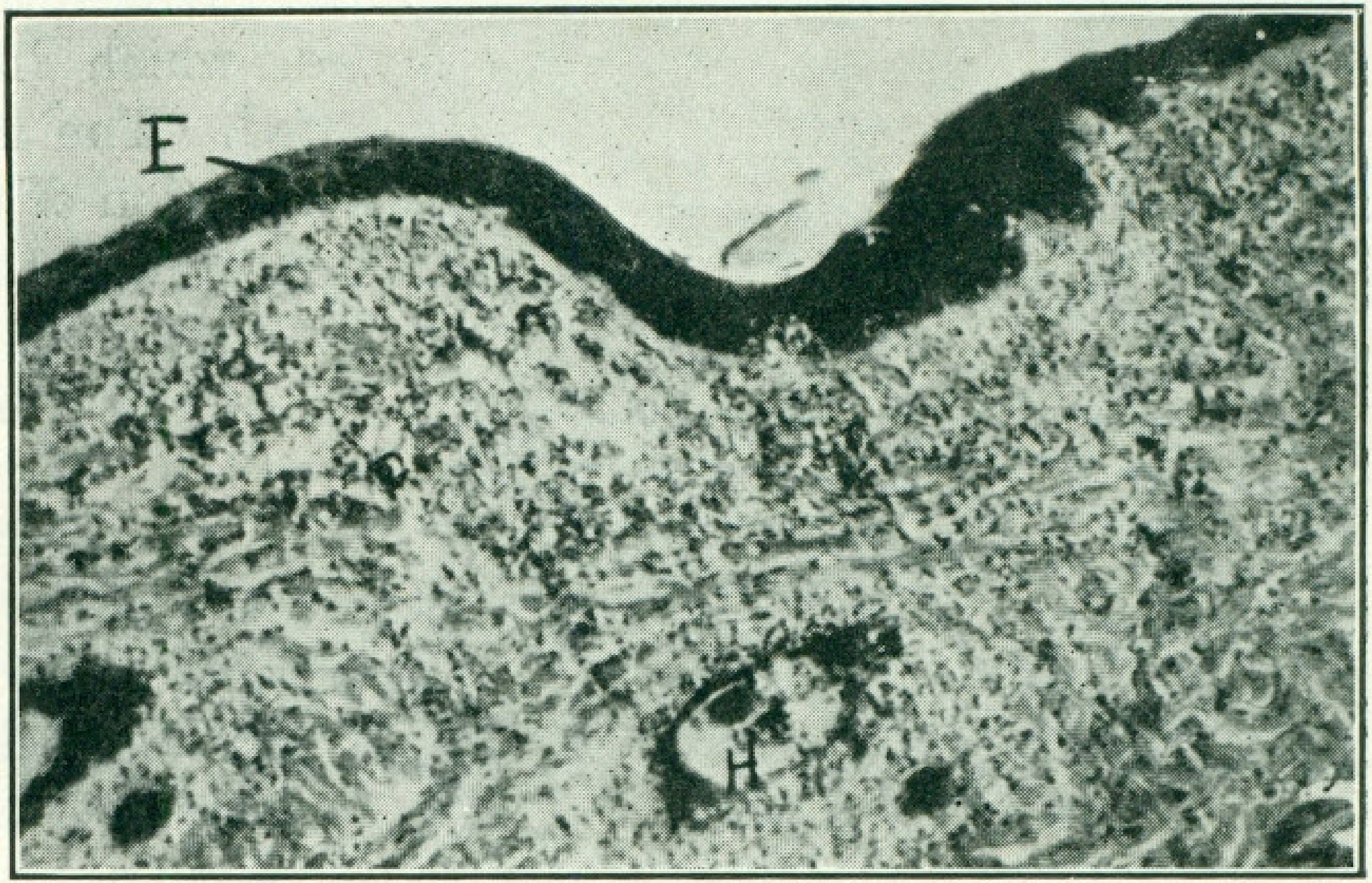

FIG. 236.—Dichlorethylsulphide, 98 hours after exposure. Thinning of epithelium (E), infiltration of corium (c) with leucocytes showing caryorrhexis. Degenerate follicles (H)