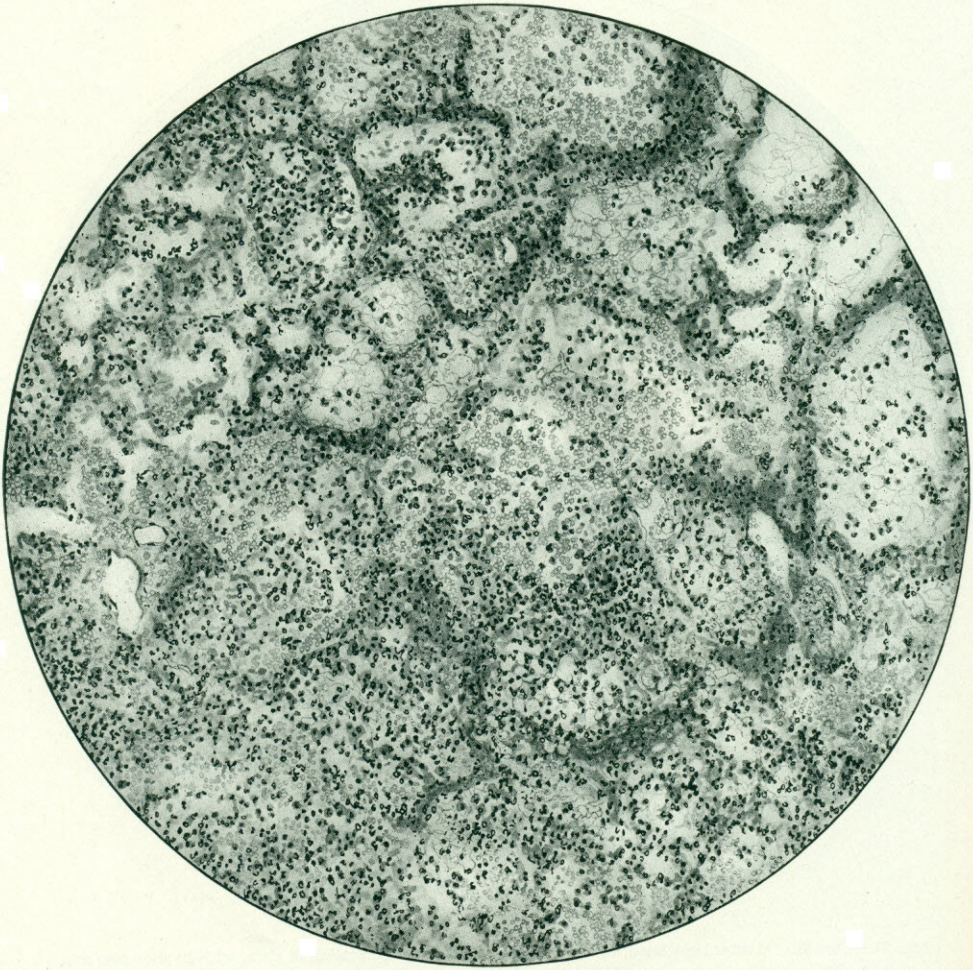

FIG. 23.—Case 22. Mustard-gas burn, 5 days' duration. Lung: Pneumonia, with necrosis of alveolar walls and nuclear fragmentation