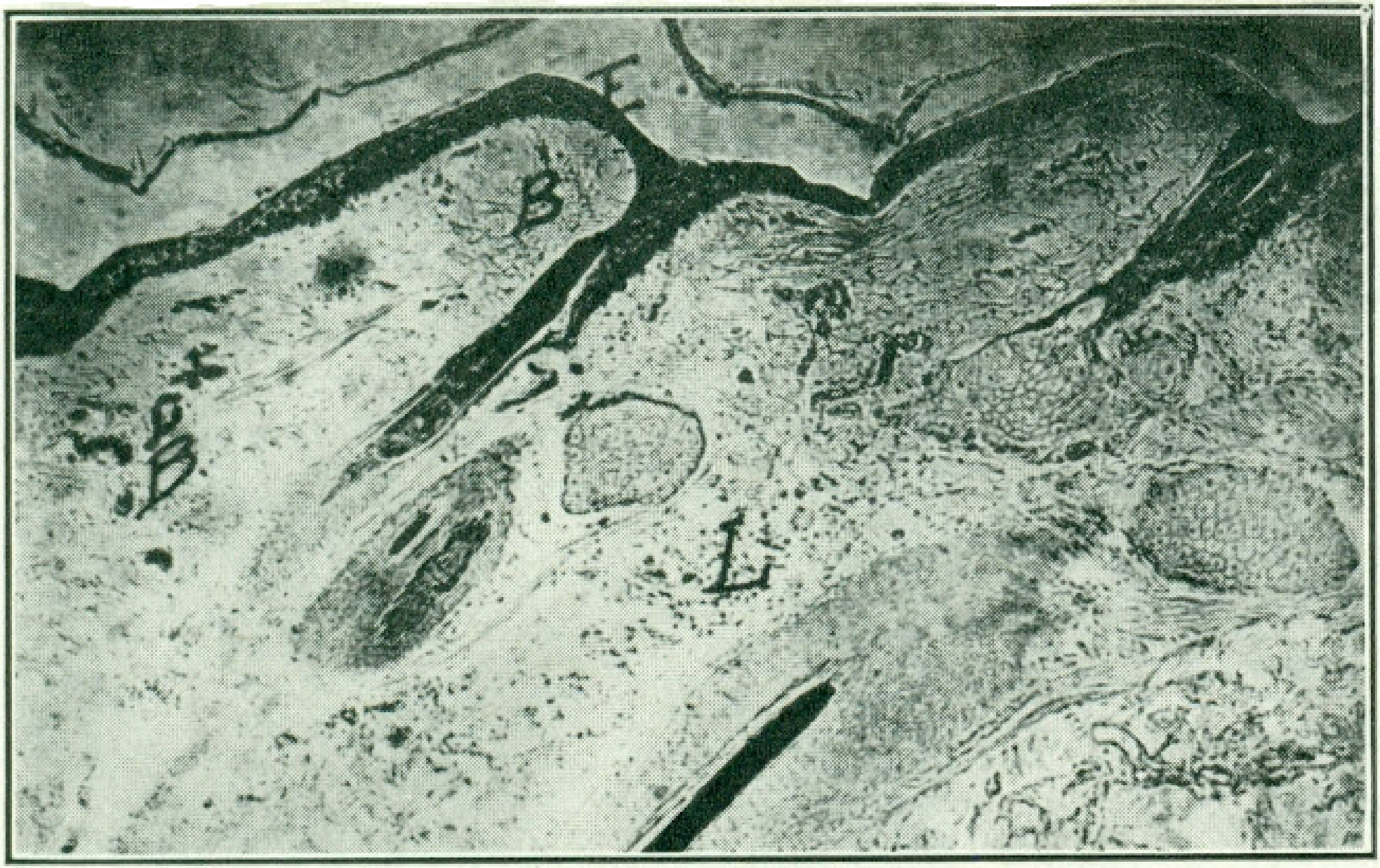

FIG. 241.—Lewisite No. 1, 24 hours after exposure. Edema leucocytes in corium (L), congestion of superficial capillaries (B) early degenerative changes and thinning of epidermis (E)